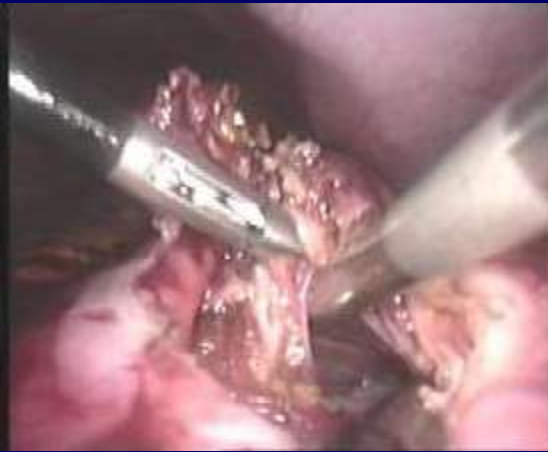



Laparoscopic Cystogastrostomy for Management of Pancreatic Congenital Cyst

Poschong Suesat M.D.

Pancreatic cysts

Pseudocysts

Congenital cysts

Cystic neoplasms

Pseudocysts

Causes - pancreatitis, blunt trauma

Symptoms - persistent abdominal pain, abdominal mass, nausea and vomiting

Complications - infected cyst, ruptured

Congenital cysts

- True cyst
- Epithelial lining (cuboidal)
- Von Hippel-Lindau disease
(cystic lesions :- brain, retina,
adrenal glands, kidneys,
pancreas)

Cystic neoplasms

1. Mucinous cystadenoma

(columnar, papillary mucin-producing epithelium)

2. Mucinous duct ectasia, IPMN

(pancreatic ducts , mucin-producing columnar epithelium
papillary projection)

3. Serous cystadenoma

(glycogen-rich cytoplasm cuboidal cells)

4. Papillary cystic tumor

(solid and pseudopapillary neoplasm)

Treatments of cystic neoplasms

Observation

(asymptomatic precancerous cysts, Serous cystadenoma)

Distal pancreatectomy

(pancreatic tail)

Pancreaticoduodenectomy

(pancreatic head)

Treatments of pseudocysts

Observation

(asymptomatic)

Resection

(pancreatic tail)

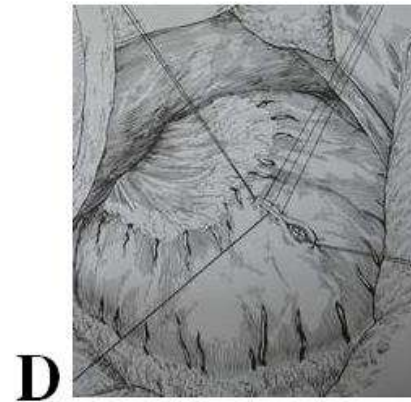
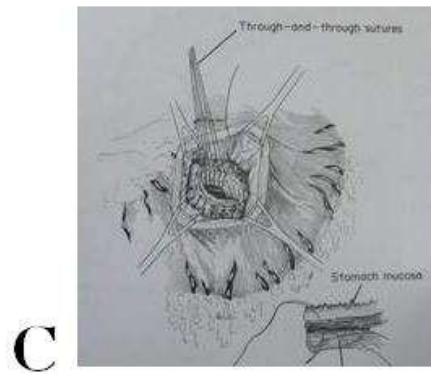
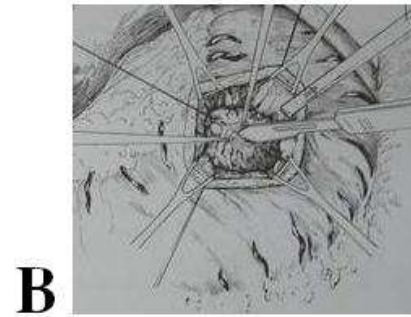
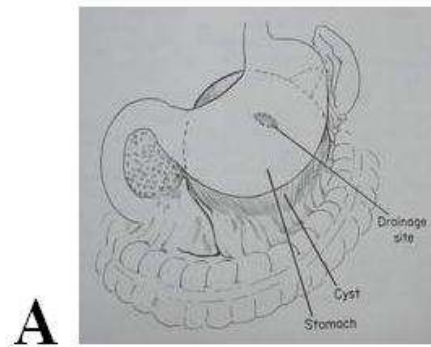
External drainage

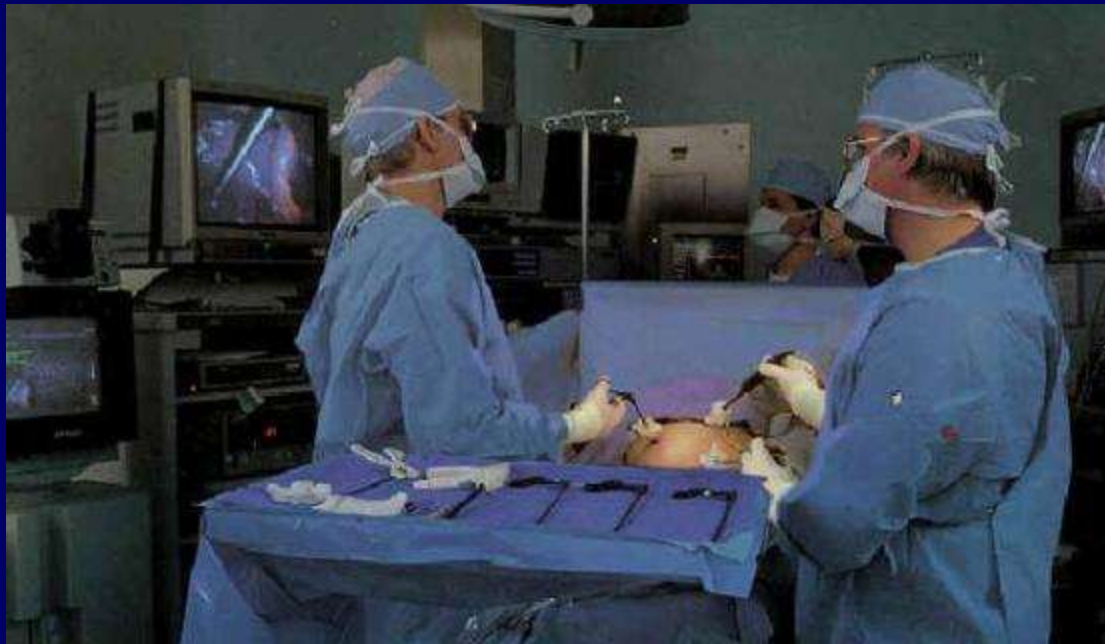(thin wall, rupture, fistula, recurrent cysts)

Internal drainage

(cystojejunostomy, cystogastrostomy, cystoduodenostomy)

Open conventional cystogastrostomy





Laparoscopic surgery

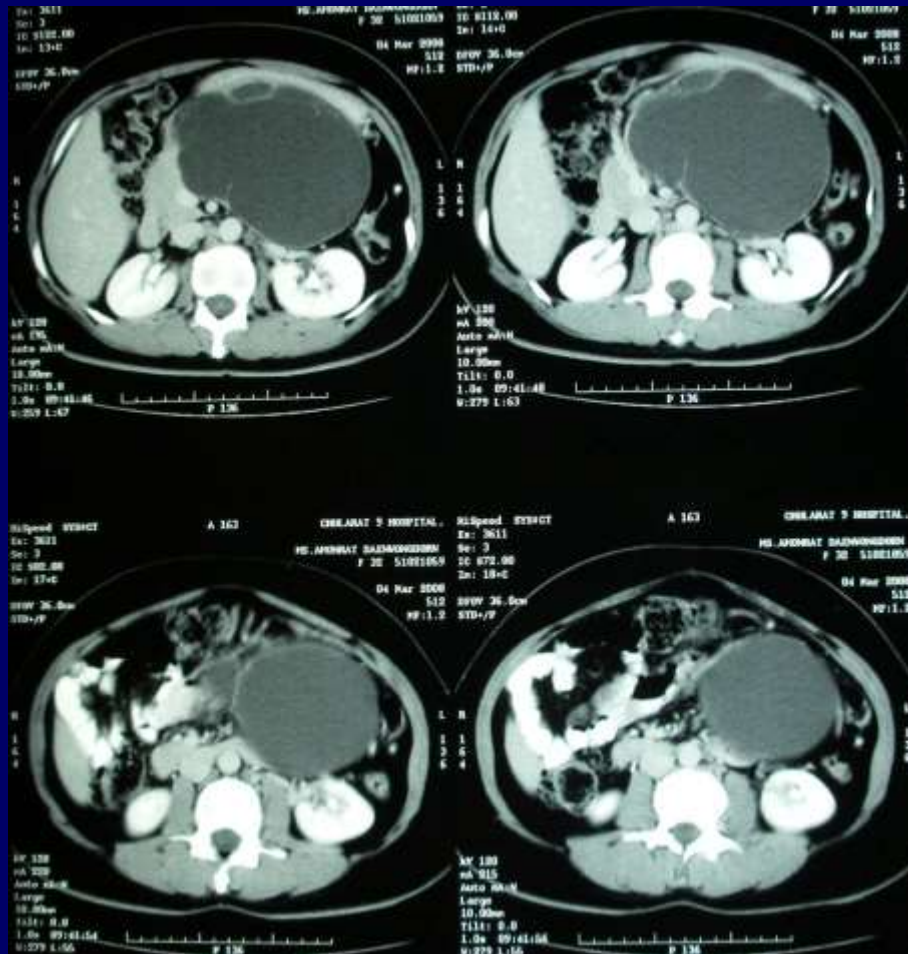
cholecystectomy

fundoplication

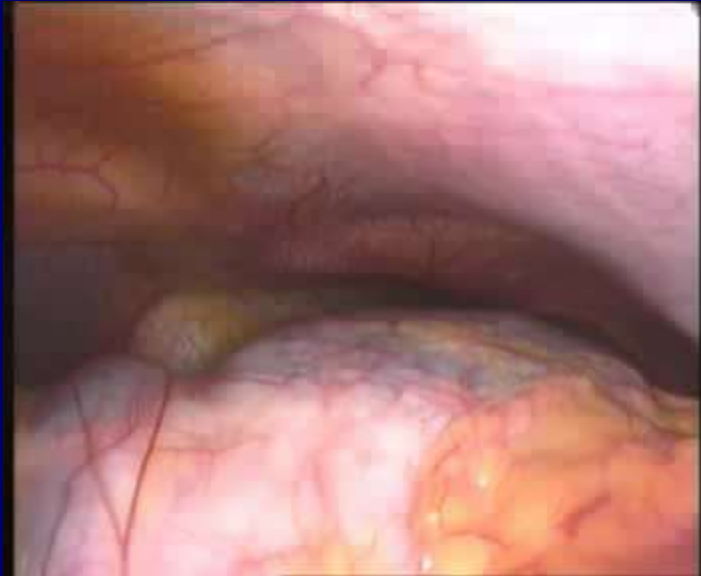
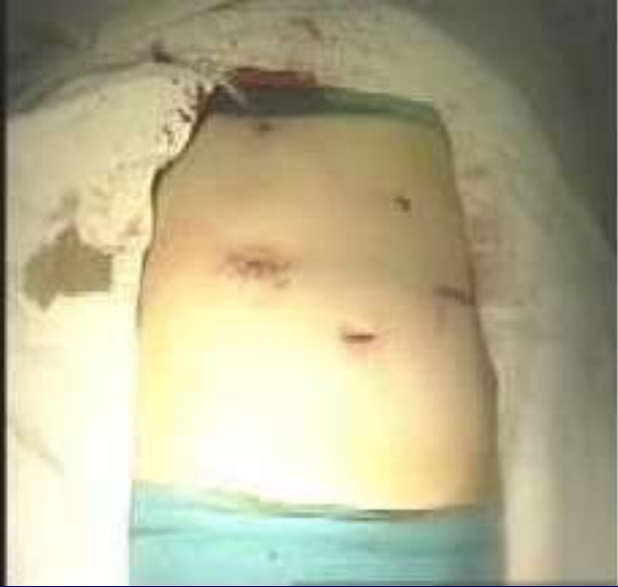splenectomy

adrenalectomy

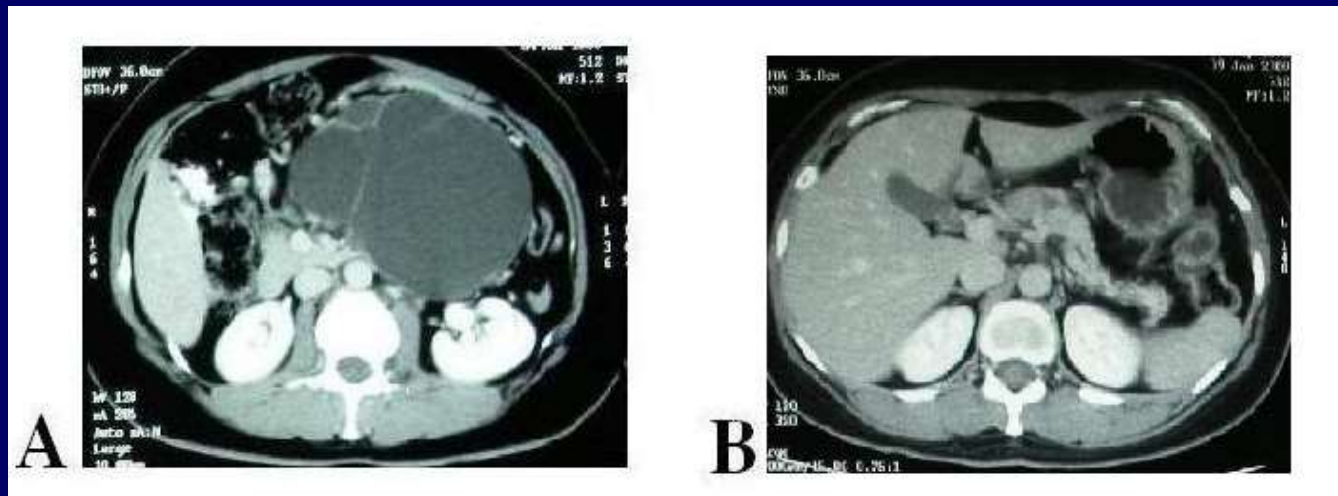
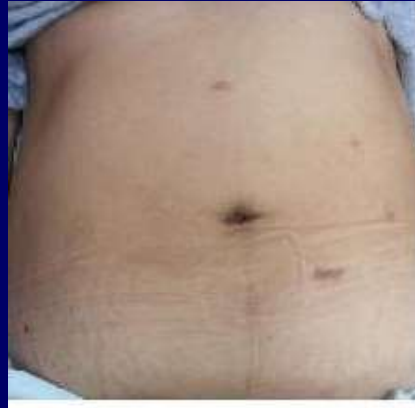Congenital cyst, a case report



Laparoscopic cystogastrostomy



Laparoscopic cystogastrostomy



Thank You

for attention