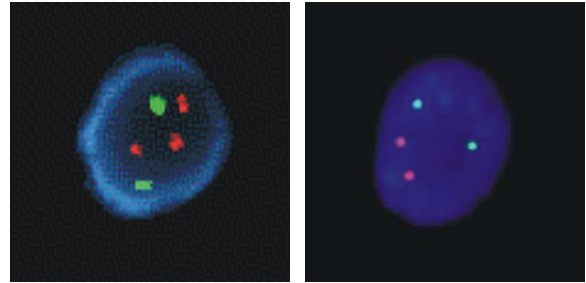
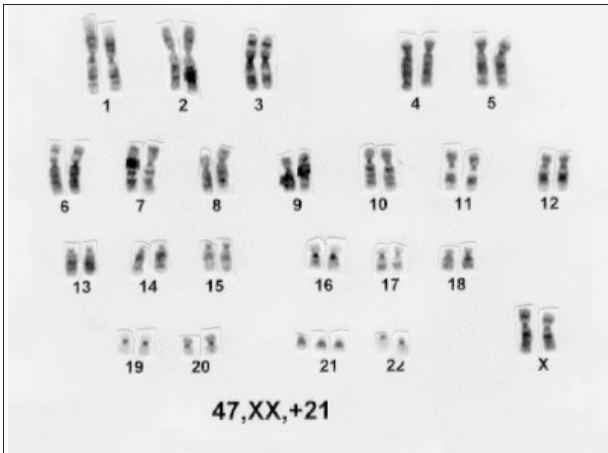
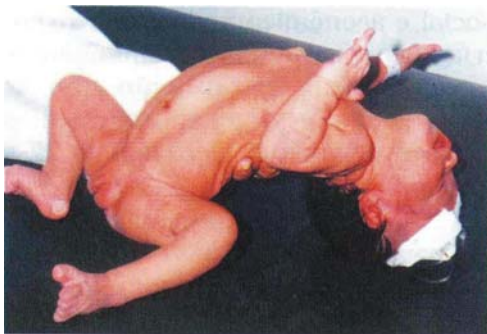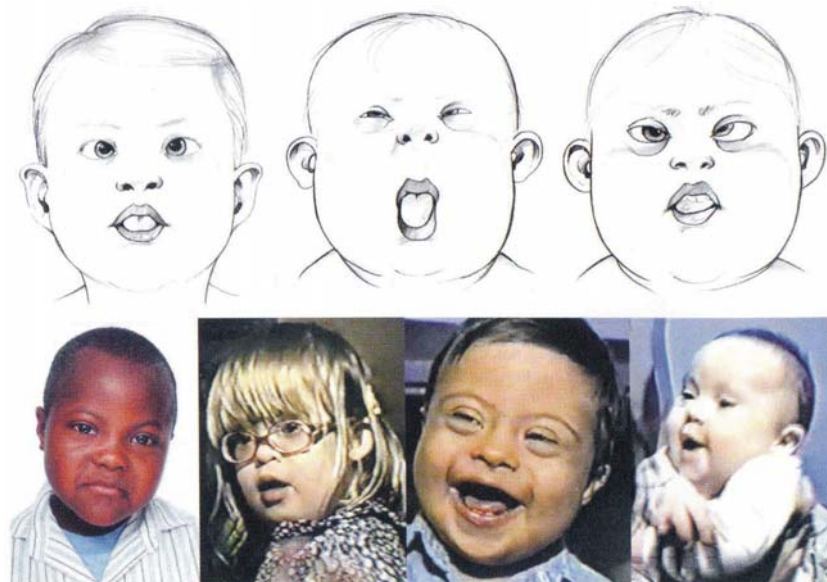


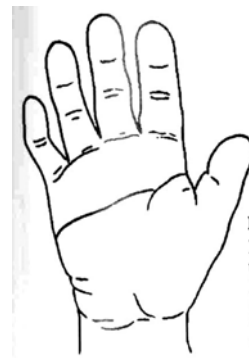# Síndrome de Down - Trissomia do 21



FISH sondas 13(verde) e 21 (vermelho)



**Figura 21.22:** Síndrome de Down característica clínica da hipotonia.



**Figura 21.21 c:** Esquema da braquidactilia com prega única unica transversa e clinodactilia.