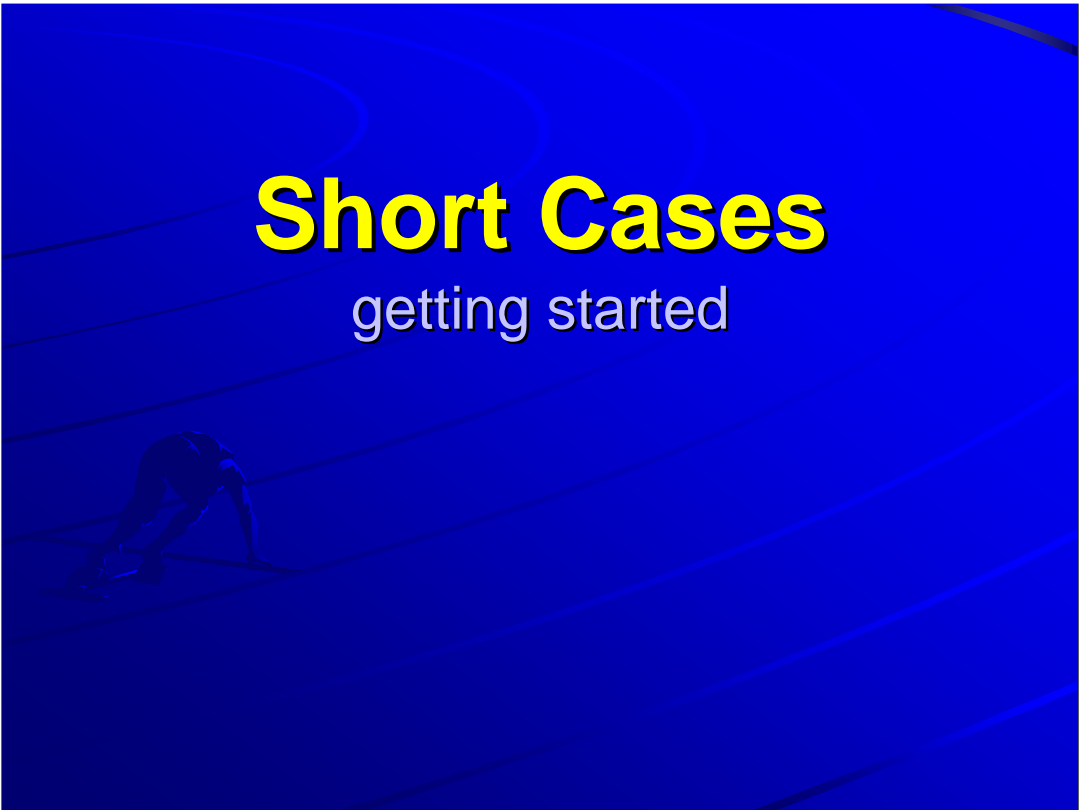


# Short Cases

## getting started



The difference (or advantage) of attaching a non-University hospital is that the patients have less annoyance to medical students.

We do not talk anymore, we will **DO** the short cases, **GET** the sign and **CONSTRUCT** an educated guess about the diagnosis

## 5 hurdles to the final goal

- ◆ Correct method
- ◆ Correct sign
- ◆ Correct interpretation
- ◆ Concise presentation
- ◆ Correct answer to the follow up questions.

In NDH, we hope we can

1. Show you the correct method
2. Appreciate the physical sign
3. Give our interpretation
4. Advise your presentation method
5. Practice the FAQs of the bedside

The final goal is, of course, get a pass in the examination.

Short case has three stages:

Setting the stage: to greet and to strip the patient

'State-of-the-art ': to demonstrate and to appreciate the sign

Ending with grace: to organize and to advertise your clinical diagnosis

And don't forget to thank the patient before you leave

# Method

- ◆ System specific
- ◆ Non-system specific

In old non-PACES system, short case examination in MRCP has both system-specific and non-system-specific elements.

The former means that the elements only apply for one system but not the examination of the other system, e.g. method of CVS examination is not applicable to that of resp. examination. An example for the latter (non-system specific element) will be 'look → feel → move' steps which are applicable to every system.

Before all these happen, the first thing should be read the questions because no matter how excellent your answer is, it will score zero if it is not the answer that the examiner is 'looking forward'

Example will be : examine this patient pulse and precordium

Then the examiner will expect you to feel the dorsalis, posterior tibial, popliteal femoral and brachial and carotid pulse before you undress the patient to examine the precordium. On the other hand, if the question is examine the CVS system, all the general examination will be expected such as clubbing, JVP, cyanosis etc.

strip before getting into your stride

To undress the patient properly is system specific and we will demonstrate to you what is adequate, what is proper and what is optimal posture of the patient during MRCP. Not broadly enough to expose/uncover patient's body decently with, your intellect is improperly exposed.

B) "State of the art": bet your best bet

Most of the examiner, if old enough, has their 'orthodox' way of 'proper' examination that cannot be challenged at all. I have believed these orthodox ways, especially during MRCP, because they have stood the test of time to be the most reproducible way to get the sign. However, these orthodox way may not lead you to the sign or destination, especially if you have never been there or seen the sign before. On the other hand, if you get the sign using other ways is better than you failed to get the sign, but you may lose your marks, depend on which marking sheet the examiner had in hand (PACES or non-PACES).

Thus if you failed to get the sign during your short case practice, you have to ask yourself whether it is your way of examination not 'orthodox' enough or you have not meet the sign 'face-to-face' before. If the former is the problem, you have to hassle Tai/Tsang/Luk/Fung or any orthodox senior as much and as soon as possible, if the latter is the problem, you have to hassle more patient ASAP and AMAP.

## 3 levels of clinical diagnosis

- ◆ Anatomical diagnosis
- ◆ Etiological diagnosis
- ◆ Functional diagnosis

As I have said before, time-keeping is extremely important in PACES. Because in the old system, time is more flexible, thus we can have few minutes to organize our answer (the clinical diagnosis) before I sell it to the examiner because it essentially involve a 'puzzle' game by putting all +ve together. However, in PACES, there is a pressure that you have to go to the next stage as the next candidate have to examine the same station. Thus if you failed to give your answer, you bound to be kicked out and the examiner cannot give you extra-time for you to organize/guide you to the answer.

It follows that your answer has to be ready before you finished the examination. How can it be done without knowing the case before the examination? A tree-like diagnostic algorithm would suit this purpose and it is system specific. I will exemplify it using examination of the chest.

At least 2 answers are expected in chest examination during MRCP for the 2 questions:

Where is the pathology: left or right, upper or lower (to localize the pathology down to which segment of the lung is impractical without a X-ray)

What is the pathology, which means: one of the following

fibrosis, collapse, pleural effusion, consolidation and pneumothorax.

As patient with pneumothorax should be drained and pneumothorax under observation can hardly match the timing of examination, its appearance in MRCP is very unlikely, though not non-existent. (What I mean is, if you offer this as your clinical diagnosis in MRCP, please think thrice)

There is both 'hard' sign and 'soft' sign in clinical examination. Hard sign are those sign you can get even your patient not cooperate with you. The soft sign are the signs that depend on the patient's cooperation as well as your appreciation and therefore very non-reproducible/unreliable. An example of 'hard sign' would be muscle wasting in chest examination. If the pectoral muscle is wasted at left side, the pathology must be at the left upper lobe and the etiology must be there in terms of months if not years, therefore cancer is unlikely. On the other hand, vocal resonance is highly depend on the loudness of patient pronouncing the vowels, thus although it is useful in clinical practice, it may be misleading during MRCP. Another example of soft sign will be the appreciation of ESM from PSM when listening to the precordium. Having said that, soft sign is useful in confirming your clinical findings but it is less useful to guide where to put your bet on.

So, what are the hard signs, what are the soft signs:

Hard sign: muscle wasting, surgical scars, diminished expansion & tracheal deviation (in order of ascending likelihood to appear in the exam)

Soft sign: percussion, decreasing in breath sound and vocal resonance – but used up more than 80% of examination time if it is to done in the orthodox way.

Please note that muscle wasting is not always present and it will easily be missed if the shoulders are not exposed by stripping off the patient down to waist. The same applies to surgical scars because most of the 'decent' scar is at the back.

Moreover, the reduction in chest expansion is easily missed if not done in the most orthodox way (you can ask CC Tsang specifically about this).

Another important point is that the localizing value of the different signs differ. The hard sign has strong localizing value but the soft are not. For example, if trachea is deviated to one side, it must be either the apical lobe is diseased or more than 50% of the lower lobe of the either side is involved. On the other hand, the percussion note, breath sound and vocal resonance are the same no matter the pathology is right or left, upper or lower.

If there are pathology over both side of the chest, muscle wasting will still persist and be present over both side of the chest but the degree of reduction in chest expansion will not be picked up on examination because it assumed that one side of the chest is 'normal'.

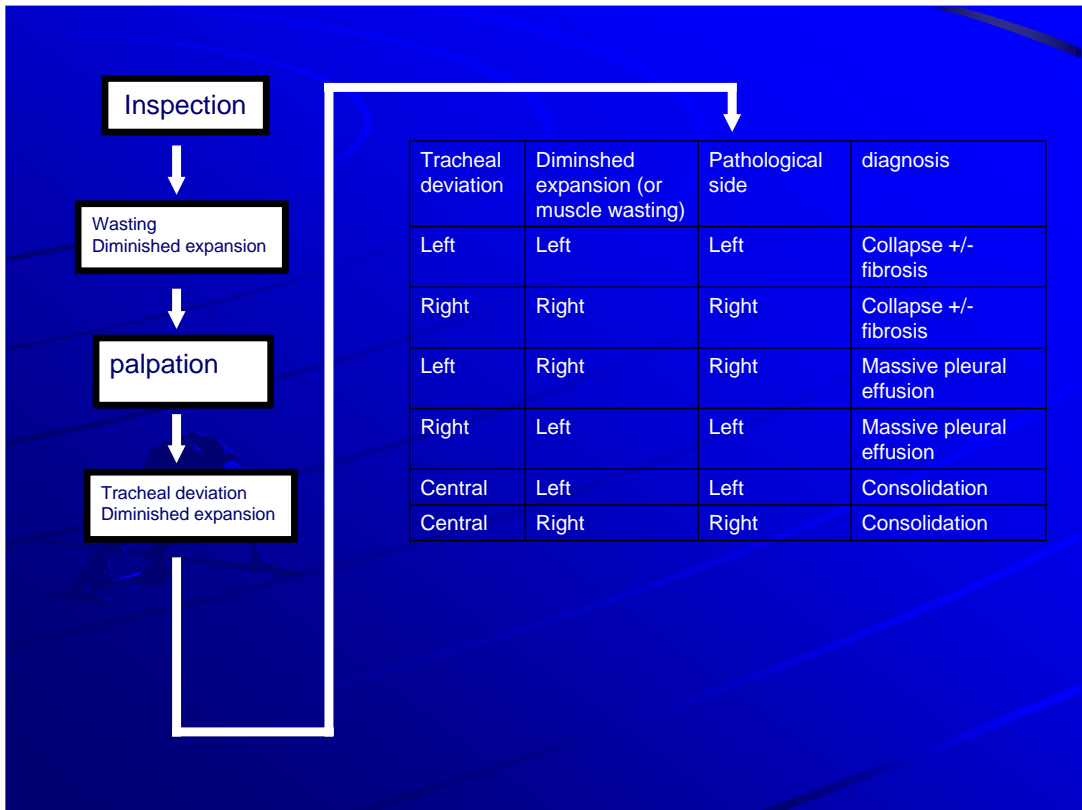
In summary, please try hard to find the hard (and the hardest) signs but don't be disappointed if they are not there. On the other hand, don't go soft in the head with the soft signs although they are also soft sell for you to sell your diagnosis to the examiners.

	Muscle wasting	Diminished expansion	Trachea deviation	Soft signs
Pleural effusion	No (must be tapped)	Same side	opposite side	<b>Stony dull*</b> ↓ breath sound ↓VR
Collapse	Yes	Same side	Same side	dull ↓ breath sound ↑VR(1)
fibrosis	Yes	Same side	Same side	dull ↓ breath sound ↓VR
consolidation	No (must be treated)	Same side	Same side	↓↓↓ ↑VR

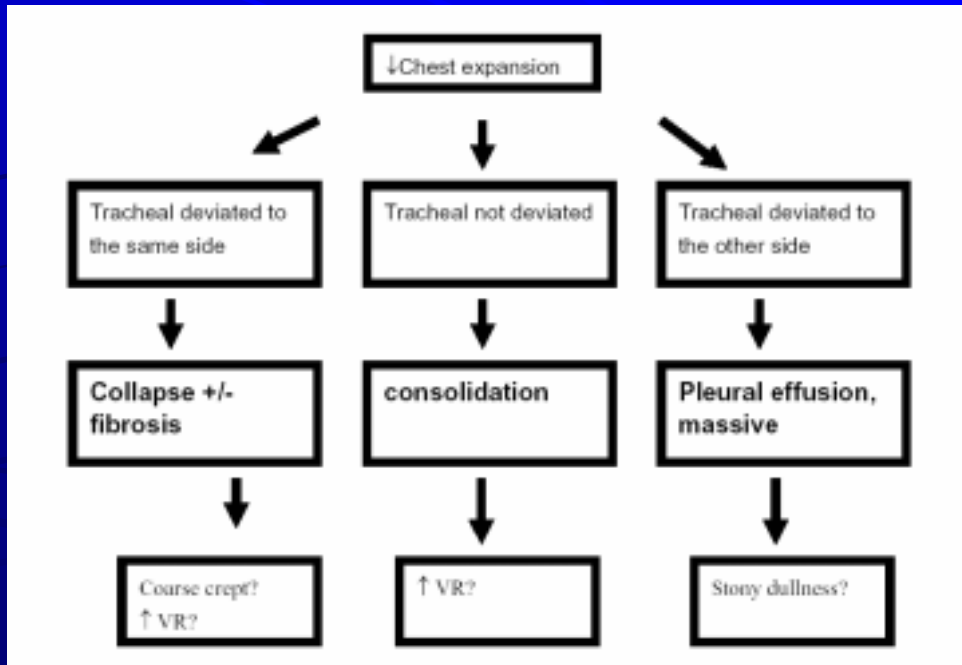
\*'hard' sign among the 'soft sign'  
(1)not sure, please check the book yourself, quite controversial

In summary, please try hard to find the hard (and the hardest) signs but don't be disappointed if they are not there. On the other hand, don't go soft in the head with the soft signs although they are also soft sell for you to sell your diagnosis to the examiners.

To simplified the diagnostic process, I will draw both a table as well as a tree diagram (**assuming >50% of lower lung involvement**)



Therefore, before you pull out your stethoscope, you have already got the idea where to pay attention to and what 'soft sign' you expect in that area to confirm your suspicion, thus hasten your mind to make up the answer before you sell it to the examiner.



# 3 types of presentations

- ◆ Prospective
- ◆ Retrospective
- ◆ Running Commentary

Lastly, there are 3 ways you can wrap your diagnosis nicely so that your examiner more likely to buy it.

'prospective' answer

presenting the +ve finding (on inspection ....on palpation ...on percussion ...on auscultation ...)  
before you sell it (so in summary, I think this patient has....)

'retrospective' answer

the diagnosis is proclaimed at the very beginning (I think this patient has MS) followed by your  
evidence (as supported by a nondisplaced apex.....)

running commentary

the signs are voiced out when you are doing the examination

In general, if the diagnosis is straightforward and you are very confident, choice 2 will impress your examiner and save you some time. However, you will be in great trouble if your bet is wrong. Choice 1 is safest because it leave you some room to argue back your mistakes and you just recount what you have done 6min ago. Running commentary is most useful when most of the sign come from inspection – such as the endocrine, skin, RA hand short cases – so that you will not forget the first sign when you get your last sign of the short cases, and you are seldom, if ever wrong. However, using this on fundoscopy examination is risky because you cannot get any clue from the examiners facial expression when you are looking at the patient's fundi with your ophthalmoscope.

In the old non-PACES system, there are usually a handful of stereotyped follow-up questions for each system. All the model questions and model answer is in the Ryder.

# 3 types of questions

- ◆ Have you finished?
  - One step further
  - Would like to do it but not actually do it
- ◆ Follow up questions
  - Relevant to the case
  - Not relevant to the case

C) The finishing touches: to organize and to advertise

An answer will gain higher mark if it is

correct – of course

supported – with both positive and negative reasons

comprehensive – including both clinical +/- functional +/- etiological diagnosis

There are many kind of diagnosis depend on what you based on e.g. a pathological diagnosis is based on pathology, therefore unless the patient was dead and you have cut out the specimen, stained it and examined it under the microscope, you cannot sell your pathological diagnosis to your examiner, in the setting of MRCP. In other words, you can never give amyloidosis as your answer in MRCP because it need apple-green birefringent tissue to be seen under the polarized light of an microscope.

The clinical diagnosis is supported by clinical sign (both +ve and -ve). For example, mitral stenosis is a clinical diagnosis supported by tapping nondisplaced apex, loud first heart sound and opening snap followed by a mid-diastolic rumbling murmur with or without a presystolic accentuation, in the absence of signs suggestive of severe AR clinically, making Austin Flint murmur instead of MS is very unlikely.

Then how to relate an etiological diagnosis in 'CLINICAL' setting? Yes! One can never be sure that AR is due to CRHD but if the mitral valve is involved, it is highly 'LIKELY', especially there is no Agrll-Roberson pupil and no habitual glue that the patient is Marfanoid.

What I want to say is that, if you can get a correct answer, you are safe. But if you can go one-step further, you will be safer.

What is one-step further?

They are the step that take you less than 5 sec but give you etiological clue and fill your diagnosis with type A evidence.

E.g. Clubbing suggest congenital heart disease as the etiology in CVS examination and carcinoma of lung in chest examination. But it will not tell you what is the congenital heart disease nor where the tumor is.

What steps take you less than 5 sec?

Signs get by inspection because taking blood pressure need more than 5 sec.

It follows that for those sign that are 'time-consuming', you will only tell the examiner you want to do but you will not actually do it yourself.

For example, you will told the examiner you would like to check the blood pressure before you finish your CVS examination and you would also examine the cranial nerve before you finish your neuro examination in the lower limbs.

You see only what you look for,

You recognize only what you know



You remember only what you  
understand