

1) The nerve, accessory, innervates which of the following muscles :

- A. infraspinatus, ulnaris lateralis, superficial digital flexor
- B. biceps brachii, sternothyroideus, common digital extensor
- \* C. omotransversarius, trapezius (cervical and thoracic parts separated by aponeurosis)
- D. anconeus, tensor fasciae antebrachii, deltoideus

The nerve accessory, innervates the following muscles : omotransversarius, trapezius (cervical and thoracic parts separated by aponeurosis).<p>

2) The nerve, axillary, innervates which of the following muscles :

- A. serratus ventralis, superficial pectoral muscles (descending and transverse), deep pectoral muscle
- \* B. deltoideus, teres major, teres minor
- C. flexor carpi radialis, lateral digital extensor, triceps brachii (lateral head)
- D. latissimus dorsi, triceps brachii (accessory head), flexor carpii ulnaris (ulnar and humeral head)

The nerve axillary, innervates the following muscles : deltoideus, teres major, teres minor.<p>

3) The nerve, caudal pectoral (c8,t1), innervates which of the following muscles :

- A. superficial digital flexor, biceps brachii, sternothyroideus
- B. infraspinatus, trapezius (cervical and thoracic parts separated by aponeurosis), ulnaris lateralis
- C. anconeus, tensor fasciae antebrachii, deltoideus
- \* D. deep pectoral muscle

The nerve caudal pectoral (c8,t1), innervates the following muscles : deep pectoral muscle.<p>

4) The nerve, cranial pectoral (c7,c8), innervates which of the following muscles :

- \* A. superficial pectoral muscles (descending and transverse)
- B. deep digital flexor (humeral, ulnar and radial head), sternocephalicus: ventral or mastoid part (sternomastoideus) and dorsal or occipital part (sterno-occipitals), supraspinatus
- C. common digital extensor, omotransversarius, coracobrachialis
- D. sternohyoideus, brachiocephalicus, brachialis

The nerve cranial pectoral (c7,c8), innervates the following muscles : superficial pectoral muscles (descending and transverse).<p>

5) The nerve, median, innervates which of the following muscles :

- A. latissimus dorsi, triceps brachii (accessory head), flexor carpii ulnaris (ulnar and humeral head)
- B. serratus ventralis, superficial pectoral muscles (descending and transverse), teres minor
- C. deep pectoral muscle, lateral digital extensor, triceps brachii (lateral head)
- \* D. flexor carpi radialis, superficial digital flexor

The nerve median, innervates the following muscles : flexor carpi radialis, superficial digital flexor and deep digital flexor.<p>

6) The nerve, musculocutaneous, innervates which of the following muscles :

- A. omotraversarius, deep digital flexor (humeral, ulnar and radial head), sternocephalicus: ventral or mastoid part (sternomastoideus) and dorsal or occipital part (sterno-occipitals)
- B. subscapularis, serratus ventralis, superficial pectoral muscles (descending and transverse)
- \* C. biceps brachii, brachialis, coracobrachialis
- D. supraspinatus, sternohyoideus, brachiocephalicus

The nerve musculocutaneous, innervates the following muscles : biceps brachii, brachialis, coracobrachialis.<p>

7) The nerve, radial, innervates which of the following muscles :

- A. deep pectoral muscle, flexor carpi radialis, latissimus dorsi
- B. flexor carpii ulnaris, rhomboideus, teres major
- C. biceps brachii, brachialis, coracobrachialis
- \* D. anconeus, common digital extensor, extensor carpi radialis

The nerve, radial, innervates the following muscles : anconeus, triceps brachii, tensor fasciae antibrachii, extensor carpi radialis, common digital extensor, lateral digital extensor, ulnaris lateralis.<p>

8) The nerve, subscapular, innervates which of the following muscles :

- A. anconeus, tensor fasciae antibrachii, deltoideus
- B. trapezius (cervical and thoracic parts separated by aponeurosis), ulnaris lateralis, superficial digital flexor
- C. biceps brachii, sternothyroideus, common digital extensor
- \* D. infraspinatus, subscapularis, supraspinatus

The nerve subscapular, innervates the following muscles : infraspinatus, subscapularis, supraspinatus.<p>


9) The nerve, thoracodorsal (c7,c8, t1), innervates which of the following muscles :

\* A. latissimus dorsi

B. deep digital flexor (humeral, ulnar and radial head), sternocephalicus: ventral or mastoid part (sternomastoideus) and dorsal or occipital part (sterno-occipitals), supraspinatus

C. common digital extensor, omotransversarius, coracobrachialis

D. sternohyoideus, brachiocephalicus, brachialis

The nerve thoracodorsal (c7,c8, t1), innervates the following muscles : latissimus dorsi. 

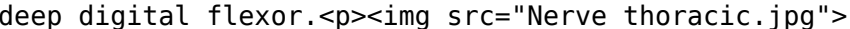
10) The nerve, ulnar, innervates which of the following muscles :

\* A. flexor carpii ulnaris (ulnar and humeral head)

B. teres minor, deep pectoral muscle, flexor carpi radialis

C. subscapularis, serratus ventralis, superficial pectoral muscles (descending and transverse)

D. lateral digital extensor, triceps brachii (lateral head), latissimus dorsi

The nerve ulnar, innervates the following muscles : flexor carpii ulnaris (ulnar and humeral head, deep digital flexor. 

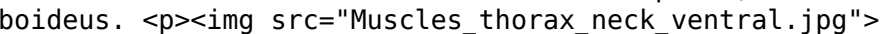
11) The nerve, ventral branches of cervical and thoracic spinal, innervates which of the following muscles :

A. anconeus, tensor fasciae antebrachii, deltoideus

B. infraspinatus, trapezius (cervical and thoracic parts separated by aponeurosis), ulnaris lateralis

C. superficial digital flexor, biceps brachii, sternothyroideus

\* D. rhomboideus

The nerve ventral branches of cervical and thoracic spinal, innervates the following muscles : rhomboideus. 

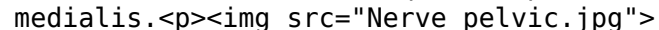
12) The nerve, femoral, innervates which of the following muscles :

\* A. quadriceps femoris rectus femoris, quadriceps femoris vastus intermedius, quadriceps femoris vastus lateralis

B. deep digital flexors, cranial tibial, gracilis

C. interosseous, psoas minor, deep gluteal

D. accessory gluteal, adductor, gastrocnemius

The nerve femoral, innervates the following muscles : quadriceps femoris rectus femoris, quadriceps femoris vastus intermedius, quadriceps femoris vastus lateralis, quadriceps femoris vastus medialis. 

13) The nerve, gluteal, innervates which of the following muscles :

- \* A. accessory gluteal, deep gluteal, middle gluteal
- B. sartorius cranial part, gemelli, semimembranosus
- C. sartorius caudal part, long digital extensor, biceps femoris
- D. pectineus, quadriceps femoris rectus femoris, popliteus

The nerve gluteal, innervates the following muscles : accessory gluteal, deep gluteal, middle gluteal, superficial gluteal, tensor fasciae latae.<p>

14) The nerve, ischiatic, innervates which of the following muscles :

- A. superficial digital flexors, lateral digital extensor, superficial gluteal
- B. quadriceps femoris vastus medialis, iliopsoas, soleus
- C. tensor fasciae latae, quadriceps femoris vastus intermedius, psoas major
- \* D. biceps femoris, gemelli, internal obturator

The nerve ischiatic, innervates the following muscles : biceps femoris, gemelli, internal obturator, quadratus femoris, semimembranosus, semitendinosus.<p>

15) The nerve, obturator, innervates which of the following muscles :

- A. deep gluteal, accessory gluteal, gastrocnemius
- B. interosseous, psoas minor, quadriceps femoris vastus lateralis
- C. deep digital flexors, cranial tibial, peroneus tertius
- \* D. adductor, external obturator, gracilis

The nerve obturator, innervates the following muscles : adductor, external obturator, gracilis, pectineus.<p>

16) The nerve, peroneal, innervates which of the following muscles :

- A. sartorius cranial part, gemelli, semimembranosus
- B. sartorius caudal part, biceps femoris, quadratus femoris
- \* C. cranial tibial, lateral digital extensor, long digital extensor
- D. pectineus, quadriceps femoris rectus femoris, popliteus

The nerve peroneal, innervates the following muscles : cranial tibial, lateral digital extensor, long digital extensor, peroneus longus, peroneus tertius.<p>

17) The nerve, saphaneous, innervates which of the following muscles :

- A. superficial gluteal, quadriceps femoris vastus medialis, iliopsoas
- B. semitendinosus, superficial digital flexors, lateral digital extensor
- \* C. sartorius caudal part, sartorius cranial part
- D. quadratus femoris, middle gluteal, internal obturator

The nerve saphaneous, innervates the following muscles : sartorius caudal part, sartorius cranial part.<p>

18) The nerve, tibial, innervates which of the following muscles :

- A. accessory gluteal, adductor, cranial tibial
- B. gracilis, peroneus tertius, pectineus
- \* C. deep digital flexors, gastrocnemius, interosseous
- D. psoas minor, quadriceps femoris vastus lateralis, deep gluteal

The nerve tibial, innervates the following muscles : deep digital flexors, gastrocnemius, interosseous, popliteus, soleus, superficial digital flexors.<p>

19) The nerve, ventral branch of thoracic & lumbar nerve, innervates which of the following muscles :

- \* A. iliopsoas, psoas major, psoas minor
- B. popliteus, sartorius cranial part, gemelli
- C. peroneus tertius, pectineus, quadriceps femoris rectus femoris
- D. semimembranosus, sartorius caudal part, long digital extensor

The nerve ventral branch of thoracic & lumbar nerve, innervates the following muscles : iliopsoas, psoas major, psoas minor.<p>

20) The artery, caudal femoral, supplies which of the following muscles :

- A. interosseous, psoas minor, quadriceps femoris vastus lateralis
- \* B. biceps femoris
- C. deep digital flexors, cranial tibial, gracilis
- D. accessory gluteal, adductor, gastrocnemius

The artery, caudal femoral, supplies the following muscles : biceps femoris.<p>

21) The artery, caudal gluteal, supplies which of the following muscles :

- A. sartorius cranial part, gemelli, semimembranosus
- \* B. accessory gluteal, superficial gluteal
- C. sartorius caudal part, long digital extensor, biceps femoris
- D. pectineus, quadriceps femoris rectus femoris, popliteus

The artery, caudal gluteal, supplies the following muscles : accessory gluteal, superficial gluteal.<p>

22) The artery, cranial gluteal, supplies which of the following muscles :

- \* A. middle gluteal
- B. deep digital flexors, cranial tibial, gracilis
- C. interosseous, psoas minor, quadriceps femoris vastus lateralis
- D. accessory gluteal, adductor, gastrocnemius

The artery, cranial gluteal, supplies the following muscles : middle gluteal.<p>

23) The artery, cranial tibial, supplies which of the following muscles :

- \* A. cranial tibial, lateral digital extensor, long digital extensor
- B. gemelli, semimembranosus, sartorius caudal part
- C. biceps femoris, quadratus femoris, middle gluteal
- D. quadriceps femoris rectus femoris, popliteus, sartorius cranial part

The artery, cranial tibial, supplies the following muscles : cranial tibial, lateral digital extensor, long digital extensor, peroneus longus, peroneus tertius.<p>

25) The artery, femoral, supplies which of the following muscles :

- \* A. quadriceps femoris rectus femoris, quadriceps femoris vastus intermedius, quadriceps femoris vastus lateralis
- B. interosseous, psoas minor, accessory gluteal
- C. cranial tibial, gracilis, peroneus tertius
- D. adductor, gastrocnemius, deep digital flexors

The artery, femoral, supplies the following muscles : quadriceps femoris rectus femoris, quadriceps femoris vastus intermedius, quadriceps femoris vastus lateralis, quadriceps femoris vastus medialis, sartorius caudal part, sartorius cranial part.<p>

28) Which of the following correctly describes the muscle, biceps femoris?

- A. Origin - humerus; Insertion - carpal, metacarpal; Innervation - radial
- B. Origin - humerus; Insertion - skull & neck; Innervation - accessory and ventral branches of cervical spinal
- \* C. Origin - ischium; Insertion - patella, tibia, calcaneus; Innervation - ischiatic
- D. Origin - humerus; Insertion - olecranon; Innervation - radial

Muscle biceps femoris belongs to the muscle group, caudal thigh. <p>It originates on the <b>ischium</b> (ischiatric tuberosity & sacrotuberous ligament). It inserts on the <b>patella, tibia, calcaneus</b> (by means of the fascia lata & crural fascia to the patella, patellar ligament, & cranial border of the tibia; by means of the crural fascia to the subcutaneous part of the tibial body; the calcaneous tuberosity). <p>It extends the hip, stifle, & hock caudal part of muscle flexes the stifle. <p>Innervation is by the <b>ischiatic</b> (it also innervates the gemelli, internal obturator, quadratus femoris, semimembranosus, semitendinosus). <p>Blood supply is by the <b>caudal femoral</b> (it also supplies the \*\*\* None Found \*\*\*). <p>Addl. Notes : in ruminants, gluteobiceps is a fusion of biceps femoris and superficial gluteal. <p>It originates on the <b>ischium</b> (ischiatric tuberosity). It inserts on the <b>femur, tibia</b> (the distal medial lip of the caudal rough surface of the femur & the proximal end of the tibia). <p>It extends the hip the part that attaches to the femur extends the stifle; the part that attaches to the tibia flexes & extends the stifle, depending on the position of the limb. <p>Innervation is by the <b>ischiatic</b> (it also innervates the biceps femoris, gemelli, internal obturator, quadratus femoris, semitendinosus). <p>Blood supply is by the <b>medial circumflex femoral</b> (it also supplies the adductor, gracilis, pectineus, semitendinosus, tensor fasciae latae). <p>Addl. Notes : the horse has a vertebral head as well as the pelvic head (all species) no major difference between 2 heads. <p>

31) Which of the following correctly describes the muscle, sartorius cranial part?

A. Origin - ilium; Insertion - femur; Innervation - gluteal

\* B. Origin - ilium; Insertion - patella; Innervation - saphaneous

C. Origin - humerus; Insertion - phalanges; Innervation - radial

D. Origin - spine; Insertion - humerus; Innervation - thoracodorsal (c7,c8, t1)

Muscle sartorius cranial part belongs to the muscle group, medial thigh. <p>It originates on the <b>ilium</b> (crest of the ilium & the thoracolumbar fascia). It inserts on the <b>patella</b> (patella, along with the rectus femoris of the quadriceps). <p>It flexes the hip, extends the stifle. <p>Innervation is by the <b>saphaneous</b> (it also innervates the sartorius caudal part). <p>Addl. Notes : unsure about blood supply. <p>

32) Which of the following correctly describes the muscle, sartorius caudal part?

\* A. Origin - ilium; Insertion - tibia; Innervation - saphaneous

B. Origin - pubis; Insertion - femur; Innervation - obturator

C. Origin - femur; Insertion - calcaneous tuberosity; Innervation - tibial

D. Origin - tibia, fibula; Insertion - distal phalanges; Innervation - tibial

Muscle sartorius caudal part belongs to the muscle group, medial thigh. <p>It originates on the <b>ilium</b> (cranial ventral iliac spine & the adjacent ventral border of the ilium). It inserts on the <b>tibia</b> (cranial border of the tibia in common with the gracilis). <p>It flexes the hip, flexes the stifle. <p>Innervation is by the <b>saphaneous</b> (it also innervates the sartorius cranial part). <p>Addl. Notes : unsure about blood supply. <p>

33) Which of the following correctly describes the muscle, gracilis?

- \* A. Origin - pubis; Insertion - medial stifle; Innervation - obturator
- B. Origin - scapula; Insertion - humerus; Innervation - axillary
- C. Origin - scapula; Insertion - olecranon; Innervation - radial
- D. Origin - tibia; Insertion - metatarsals i & ii; Innervation - peroneal

Muscle gracilis belongs to the muscle group, medial thigh. <p>It originates on the <b>pubis</b> (pelvic symphysis by means of the symphyseal tendon). It inserts on the <b>medial stifle</b> (cranio-medial border of the tibia). <p>It adducts the limb, flexes the stifle, extends the hip & hock. <p>Innervation is by the <b>obturator</b> (it also innervates the adductor, external obturator, pectineus). <p>Blood supply is by the <b>medial circumflex femoral</b> (it also supplies the adductor, pectineus, semimembranosus, semitendinosus, tensor fasciae latae). <p>Addl. Notes : Caution : some conflicting information found. <p>

34) Which of the following correctly describes the muscle, pectineus?

- A. Origin - sternum; Insertion - humerus; Innervation - caudal pectoral (c8,t1)
- \* B. Origin - pubis; Insertion - femur; Innervation - obturator
- C. Origin - humerus; Insertion - metacarpals; Innervation - radial
- D. Origin - femur; Insertion - metatarsals; Innervation - peroneal

Muscle pectineus belongs to the muscle group, medial thigh. <p>It originates on the <b>pubis</b> (body of the pubis on each side, from the iliopubic eminence to the pubic tubercle). It inserts on the <b>femur</b> (distal end of the medial lip of the caudal rough surface of the femur). <p>It adducts the limb. <p>Innervation is by the <b>obturator</b> (it also innervates the adductor, external obturator, gracilis). <p>Blood supply is by the <b>medial circumflex femoral</b> (it also supplies the adductor, gracilis, semimembranosus, semitendinosus, tensor fasciae latae). <p>Addl. Notes : Caution : some conflicting information found. <p>

35) Which of the following correctly describes the muscle, adductor?

- A. Origin - ilium; Insertion - tibia; Innervation - femoral
- B. Origin - skull; Insertion - scapula; Innervation - ventral branches of cervical and thoracic spinal
- \* C. Origin - pubis; Insertion - femur; Innervation - obturator
- D. Origin - sternum; Insertion - basihyoid bone; Innervation - ventral branches of cervical spinal

Muscle adductor belongs to the muscle group, medial thigh. <p>It originates on the <b>pubis</b> (the entire pelvic symphysis by means of the symphyseal tendon, the adjacent part of the ischiatic arch, & ventral surface of the pubis & ischium). It inserts on the <b>femur</b> (entire lateral lip of the caudal rough surface of the femur). <p>It adducts the limb & extends the hip. <p>Innervation is by the <b>obturator</b> (it also innervates the external obturator, gracilis, pectineus). <p>Blood supply is by the <b>medial circumflex femoral</b> (it also supplies the gracilis, pectineus, semimembranosus, semitendinosus, tensor fasciae latae). <p>Addl. Notes : Caution : some conflicting information found. <p>

36) Which of the following correctly describes the muscle, tensor fasciae latae?

- \* A. Origin - ilium; Insertion - femur; Innervation - gluteal
- B. Origin - latissimus fascia; Insertion - olecranon; Innervation - radial
- C. Origin - humerus; Insertion - ulna, radius; Innervation - musculocutaneous
- D. Origin - femur; Insertion - tibia; Innervation - tibial

Muscle tensor fasciae latae belongs to the muscle group, lateral pelvis. <p>It originates on the <b>ilium</b> (tuber coxae & adjacent part of the ilium; & the aponeurosis of the middle gluteal muscle). It inserts on the <b>femur</b> (lateral femoral fascia). <p>It tenses the lateral femoral fascia, flexes the hip, & extends the stifle. <p>Innervation is by the <b>gluteal</b> (it also innervates the accessory gluteal, deep gluteal, middle gluteal, superficial gluteal). <p>Blood supply is by the <b>medial circumflex femoral</b> (it also supplies the adductor, gracilis, pectineus, semimembranosus, semitendinosus). <p>Addl. Notes : unsure about blood supply. <p>

37) Which of the following correctly describes the muscle, superficial gluteal?

- \* A. Origin - sacrum, ilium; Insertion - femur; Innervation - gluteal
- B. Origin - ilium; Insertion - patella; Innervation - saphaneous
- C. Origin - latissimus fascia; Insertion - olecranon; Innervation - radial
- D. Origin - humerus; Insertion - ulna, radius; Innervation - musculocutaneous

Muscle superficial gluteal belongs to the muscle group, lateral pelvis. <p>It originates on the <b>sacrum, ilium</b> (lateral border of the sacrum & the first caudal vertebra, partly by means of the sacrotuberous ligament; the cranial dorsal iliac spine by means of the deep gluteal fascia). It inserts on the <b>femur</b> (third trochanter). <p>It extends the hip & abducts the limb. <p>Innervation is by the <b>gluteal</b> (it also innervates the accessory gluteal, deep gluteal, middle gluteal, tensor fasciae latae). <p>Blood supply is by the <b>caudal gluteal</b> (it also supplies the accessory gluteal). <p>

38) Which of the following correctly describes the muscle, middle gluteal?

- A. Origin - humerus; Insertion - carpal, metacarpal; Innervation - radial
- B. Origin - humerus; Insertion - olecranon; Innervation - radial
- C. Origin - humerus; Insertion - skull & neck; Innervation - accessory and ventral branches of cervical spinal
- \* D. Origin - ilium; Insertion - femur; Innervation - gluteal

Muscle middle gluteal belongs to the muscle group, lateral pelvis. <p>It originates on the <b>ilium</b> (wing of ilium). It inserts on the <b>femur</b> (caudal greater trochanter). <p>It extends & abducts the hip, rotates the pelvic limb medially. <p>Innervation is by the <b>gluteal</b> (it also innervates the accessory gluteal, deep gluteal, superficial gluteal, tensor fasciae latae). <p>Blood supply is by the <b>cranial gluteal</b> (it also supplies the \*\*\* None Found \*\*\*). <p>

39) Which of the following correctly describes the muscle, deep gluteal?

- A. Origin - metatarsals; Insertion - proximal sesamoid and digital extensor tendon; Innervation - tibial
- B. Origin - femur; Insertion - tibia; Innervation - femoral
- C. Origin - spinal column; Insertion - ilium; Innervation - ventral branch of thoracic & lumbar nerve
- \* D. Origin - ilium; Insertion - femur; Innervation - gluteal

Muscle deep gluteal belongs to the muscle group, lateral pelvis. <p>It originates on the <b>ilium</b> (body of the ilium & ischiatic spine). It inserts on the <b>femur</b> (cranial aspect of greater trochanter). <p>It extends & abducts the hip, & rotates the pelvic limb medially. <p>Innervation is by the <b>gluteal</b> (it also innervates the accessory gluteal, middle gluteal, superficial gluteal, tensor fasciae latae). <p>

40) Which of the following correctly describes the muscle, accessory gluteal?

- A. Origin - first rib; Insertion - thyroid cartilage; Innervation - ventral branches of cervical spinal
- \* B. Origin - ilium; Insertion - femur; Innervation - gluteal
- C. Origin - humerus; Insertion - phalanges; Innervation - radial
- D. Origin - scapula; Insertion - humerus; Innervation - subscapular

Muscle accessory gluteal belongs to the muscle group, lateral pelvis. <p>It originates on the <b>ilium</b> (cranial dorsal iliac spine by means of the deep gluteal fascia). It inserts on the <b>femur</b> (third trochanter). <p>It extends the hip & abducts the limb. <p>Innervation is by the <b>gluteal</b> (it also innervates the deep gluteal, middle gluteal, superficial gluteal, tensor fasciae latae). <p>Blood supply is by the <b>caudal gluteal</b> (it also supplies the superficial gluteal). <p>Addl. Notes : part of the middle gluteal in ungulates only. <p>

41) Which of the following correctly describes the muscle, internal obturator?

- A. Origin - humerus; Insertion - olecranon; Innervation - radial
- B. Origin - ilium; Insertion - femur; Innervation - gluteal
- C. Origin - spine; Insertion - humerus; Innervation - thoracodorsal (c7,c8, t1)
- \* D. Origin - pubis, ischium; Insertion - femur; Innervation - ischiatic

Muscle internal obturator belongs to the muscle group, caudal hip. <p>It originates on the <b>pubis, ischium</b> (the symphysis & the dorsal surface of the ischium & pubis). It inserts on the <b>femur</b> (trochanteric fossa). <p>It rotates the pelvic limb laterally at the hip. <p>Innervation is by the <b>ischiatic</b> (it also innervates the biceps femoris, gemelli, quadratus femoris, semimembranosus, semitendinosus). <p>Blood supply is by the <b>deep femoral</b> (it also supplies the external obturator, gemelli, quadratus femoris). <p>Addl. Notes : unsure about blood supply could be deep femoral or branches (like medial circumflex femoral). <p>

42) Which of the following correctly describes the muscle, gemelli?

- A. Origin - humerus; Insertion - phalanges; Innervation - radial
- B. Origin - pubis; Insertion - femur; Innervation - obturator
- C. Origin - femur; Insertion - calcaneous tuberosity; Innervation - tibial
- \* D. Origin - ischium; Insertion - femur; Innervation - ischiatic

Muscle gemelli belongs to the muscle group, caudal hip. <p>It originates on the <b>ischium</b> (lateral surface of the ischium, caudal to the acetabulum & ventral to the lesser ischiatic notch). It inserts on the <b>femur</b> (trochanteric fossa). <p>It rotates the pelvic limb laterally at the hip. <p>Innervation is by the <b>ischiatic</b> (it also innervates the biceps femoris, internal obturator, quadratus femoris, semimembranosus, semitendinosus). <p>Blood supply is by the <b>deep femoral</b> (it also supplies the external obturator, internal obturator, quadratus femoris). <p>Addl. Notes : unsure about blood supply could be deep femoral or branches (like medial circumflex femoral). <p>It originates on the <b>pubis, ischium</b> (ventral surface of the pubis & ischium). It inserts on the <b>femur</b> (trochanteric fossa). <p>It rotates the pelvic limb laterally, adducts thigh (?). <p>Innervation is by the <b>obturator</b> (it also innervates the adductor, gracilis, pectineus). <p>Blood supply is by the <b>deep femoral</b> (it also supplies the gemelli, internal obturator, quadratus femoris). <p>Addl. Notes : unsure about blood supply could be deep femoral or branches (like medial circumflex femoral). <p>

46) Which of the following correctly describes the muscle, quadriceps femoris vastus lateralis?

- \* A. Origin - femur; Insertion - tibia; Innervation - femoral
- B. Origin - latissimus fascia; Insertion - olecranon; Innervation - radial
- C. Origin - pubis; Insertion - femur; Innervation - obturator
- D. Origin - femur; Insertion - tibia; Innervation - tibial

Muscle quadriceps femoris vastus lateralis belongs to the muscle group, cranial thigh. <p>It originates on the <b>femur</b> (proximal part of the lateral lip of the caudal rough surface of the femur). It inserts on the <b>tibia</b> (tibial tuberosity (via patella)). <p>It extends the stifle. <p>Innervation is by the <b>femoral</b> (it also innervates the quadriceps femoris rectus femoris, quadriceps femoris vastus intermedius, quadriceps femoris vastus medialis). <p>Blood supply is by the <b>femoral</b> (it also supplies the quadriceps femoris rectus femoris, quadriceps femoris vastus intermedius, quadriceps femoris vastus medialis, sartorius caudal part, sartorius cranial part). <p>Addl. Notes : unsure about blood supply could be deep femoral, femoral or saphenous. <p>It originates on the <b>femur</b> (medial side of the proximal end of the cranial surface of the femur & the proximal end of the medial lip of the caudal rough surface). It inserts on the <b>tibia</b> (tibial tuberosity (via patella)). <p>It extends the stifle. <p>Innervation is by the <b>femoral</b> (it also innervates the quadriceps femoris rectus femoris, quadriceps femoris vastus intermedius, quadriceps femoris vastus lateralis). <p>Blood supply is by the <b>femoral</b> (it also supplies the quadriceps femoris rectus femoris, quadriceps femoris vastus intermedius, quadriceps femoris vastus lateralis, sartorius caudal part, sartorius cranial part). <p>Addl. Notes : unsure about blood supply could be deep femoral, femoral or saphenous. <p>

49) Which of the following correctly describes the muscle, iliopsoas?

- \* A. Origin - lumbar vertebrae (psoas major), wing of ilium (iliacus); Insertion - femur; Innervation - ventral branch of thoracic & lumbar nerve and femoral
- B. Origin - femur; Insertion - tibia; Innervation - femoral
- C. Origin - humerus; Insertion - phalanges; Innervation - radial
- D. Origin - metatarsals; Insertion - proximal sesamoid and digital extensor tendon; Innervation - tibial

Muscle iliopsoas belongs to the muscle group, cranial thigh. <p>It originates on the <b>lumbar vertebrae (psoas major), wing of ilium (iliacus)</b> (transverse processes & bodies of the lumbar vertebrae (psoas major), wing of ilium (iliacus)). It inserts on the <b>femur</b> (lesser trochanter). <p>It flexes the hip, outward rotation of thigh. <p>Innervation is by the <b>ventral branch of thoracic & lumbar nerve</b> (it also innervates the psoas major, psoas minor). Innervation also provided by <b>femoral</b>. <p>Blood supply is by the <b>[unknown]</b> (it also supplies the psoas major, psoas minor). <p>

50) Which of the following correctly describes the muscle, psoas major?

- A. Origin - humerus; Insertion - olecranon; Innervation - radial
- B. Origin - scapula; Insertion - humerus; Innervation - subscapular
- C. Origin - first rib; Insertion - thyroid cartilage; Innervation - ventral branches of cervical spinal
- \* D. Origin - spinal column; Insertion - femur; Innervation - ventral branch of thoracic & lumbar nerve

Muscle psoas major belongs to the muscle group, cranial thigh. <p>It originates on the <b>spinal column</b> (transverse processes & bodies of the lumbar vertebrae). It inserts on the <b>femur</b> (lesser trochanter). <p>It flexes the hip, outward rotation of thigh. <p>Innervation is by the <b>ventral branch of thoracic & lumbar nerve</b> (it also innervates the iliopsoas, psoas minor). <p>Blood supply is by the <b>[unknown]</b> (it also supplies the iliopsoas, psoas minor). <p>

51) Which of the following correctly describes the muscle, psoas minor?

- A. Origin - ilium; Insertion - femur; Innervation - gluteal
- B. Origin - spine; Insertion - humerus; Innervation - thoracodorsal (c7,c8, t1)
- \* C. Origin - spinal column; Insertion - ilium; Innervation - ventral branch of thoracic & lumbar nerve
- D. Origin - humerus; Insertion - phalanges; Innervation - radial

Muscle psoas minor belongs to the muscle group, cranial thigh. <p>It originates on the <b>spinal column</b> (transverse processes & bodies of the thoracic and lumbar vertebrae (t13 to l5)). It inserts on the <b>ilium</b> (body of ilium). <p>It stabilize back. <p>Innervation is by the <b>ventral branch of thoracic & lumbar nerve</b> (it also innervates the iliopsoas, psoas major). <p>Blood supply is by the <b>[unknown]</b> (it also supplies the iliopsoas, psoas major). <p>

52) Which of the following correctly describes the muscle, cranial tibial?

- A. Origin - humerus; Insertion - phalanges; Innervation - radial
- B. Origin - femur; Insertion - calcaneous tuberosity; Innervation - tibial
- C. Origin - pubis; Insertion - femur; Innervation - obturator
- \* D. Origin - tibia; Insertion - metatarsals i & ii; Innervation - peroneal

Muscle cranial tibial belongs to the muscle group, craniolateral leg. <p>It originates on the <b>tibia</b> (the tibial tuberosity & the adjacent articular margin of the tibia; the lateral edge of the cranial tibial border). It inserts on the <b>metatarsals i & ii</b> (dorsal surface of the base of mt i & ii). <p>It flexes the tarsus & rotates the paw laterally. <p>Innervation is by the <b>peroneal</b> (it also innervates the lateral digital extensor, long digital extensor, peroneus longus, peroneus tertius). <p>Blood supply is by the <b>cranial tibial</b> (it also supplies the lateral digital extensor, long digital extensor, peroneus longus, peroneus tertius). <p>Addl. Notes : blood supply assumed based on location (nothing definitive found in notes or online). <p>

54) Which of the following correctly describes the muscle, peroneus longus?

- A. Origin - humerus; Insertion - metacarpals; Innervation - radial
- B. Origin - sternum; Insertion - humerus; Innervation - caudal pectoral (c8,t1)
- \* C. Origin - stifle; Insertion - tarsal iv, metatarsals; Innervation - peroneal
- D. Origin - pubis; Insertion - medial stifle; Innervation - obturator

Muscle peroneus longus belongs to the muscle group, craniolateral leg. <p>It originates on the <b>stifle</b> (lateral condyle of the tibia, the proximal end of the fibula, & the lateral epicondyle of the femur by means of the lateral collateral ligament of the stifle). It inserts on the <b>tarsal iv, metatarsals</b> (the fourth tarsal bone & the plantar aspect of the base of the metatarsals). <p>It flexes the tarsus & rotates the paw medially so that the plantar surface faces laterally. <p>Innervation is by the <b>peroneal</b> (it also innervates the cranial tibial, lateral digital extensor, long digital extensor, peroneus tertius). <p>Blood supply is by the <b>cranial tibial</b> (it also supplies the cranial tibial, lateral digital extensor, long digital extensor, peroneus tertius). <p>Addl. Notes : blood supply assumed based on location (nothing definitive found in notes or online). <p>

55) Which of the following correctly describes the muscle, peroneus tertius?

- A. Origin - skull; Insertion - scapula; Innervation - ventral branches of cervical and thoracic spinal
- B. Origin - pubis; Insertion - femur; Innervation - obturator
- C. Origin - sternum; Insertion - basihyoid bone; Innervation - ventral branches of cervical spinal
- \* D. Origin - femur; Insertion - metatarsals; Innervation - peroneal

Muscle peroneus tertius <p>It originates on the <b>femur</b> (extensor fossa of femur). It inserts on the <b>metatarsals</b> . <p>It extends stifle, flexes tarsus. <p>Innervation is by the <b>peroneal</b> (it also innervates the cranial tibial, lateral digital extensor, long digital extensor, peroneus longus). <p>Blood supply is by the <b>cranial tibial</b> (it also supplies the cranial tibial, lateral digital extensor, long digital extensor, peroneus longus). <p>Addl. Notes : blood supply assumed based on location (nothing definitive found in notes or online). <p>

56) Which of the following correctly describes the hindlimb muscle, lateral digital extensor?

- \* A. Origin - fibula; Insertion - lateral digit; Innervation - peroneal
- B. Origin - humerus; Insertion - ulna, radius; Innervation - musculocutaneous
- C. Origin - latissimus fascia; Insertion - olecranon; Innervation - radial
- D. Origin - femur; Insertion - tibia; Innervation - tibial

Muscle lateral digital extensor <p>It originates on the <b>fibula</b> (\|). It inserts on the <b>lateral digit</b> . <p>It extends digits, flexes tarsus. <p>Innervation is by the <b>peroneal</b> (it also innervates the cranial tibial, long digital extensor, peroneus longus, peroneus tertius). <p>Blood supply is by the <b>cranial tibial</b> (it also supplies the cranial tibial, long digital extensor, peroneus longus, peroneus tertius). <p>Addl. Notes : blood supply assumed based on location (nothing definitive found in notes or online). <p>

57) Which of the following correctly describes the muscle, gastrocnemius?

- \* A. Origin - femur; Insertion - calcaneous tuberosity; Innervation - tibial
- B. Origin - scapula; Insertion - humerus; Innervation - subscapular
- C. Origin - humerus; Insertion - ulna, radius; Innervation - musculocutaneous
- D. Origin - ilium; Insertion - patella; Innervation - saphenous

Muscle gastrocnemius belongs to the muscle group, caudal leg. <p>It originates on the <b>femur</b> (medial & lateral supercondylar tuberosities of the femur). It inserts on the <b>calcaneous tuberosity</b> (the proximal dorsal surface of the calcaneous tuberosity). <p>It extends the tarsus & flexes the stifle. <p>Innervation is by the <b>tibial</b> (it also innervates the deep digital flexors, interosseous, popliteus, soleus, superficial digital flexors). <p>Blood supply is by the <b>caudal tibial or saphenous</b> (it also supplies the popliteus, soleus). <p>Addl. Notes : blood supply assumed based on location (nothing definitive found in notes or online). <p>

58) Which of the following correctly describes the muscle, superficial digital flexors?

- A. Origin - humerus; Insertion - skull & neck; Innervation - accessory and ventral branches of cervical spinal
- B. Origin - humerus; Insertion - carpal, metacarpal; Innervation - radial
- \* C. Origin - femur; Insertion - calcaneous tuberosity, middle phalanges of digits ii, iii, iv, & v; Innervation - tibial
- D. Origin - humerus; Insertion - olecranon; Innervation - radial

Muscle superficial digital flexors belongs to the muscle group, caudal leg. <p>It originates on the <b>femur</b> (lateral supercondylar tuberosity of the femur). It inserts on the <b>calcaneous tuberosity, middle phalanges of digits ii, iii, iv, & v</b> (calcaneous tuberosity & the bases of the middle phalanges of the functional digits). <p>It flexes the first two digital joints of the four principal digits; flexes the stifle; extends the tarsus. <p>Innervation is by the <b>tibial</b> (it also innervates the deep digital flexors, gastrocnemius, interosseous, popliteus, soleus). <p>Blood supply is by the <b>saphenous</b> (it also supplies the deep digital flexors). <p>Addl. Notes : blood supply assumed based on location (nothing definitive found in notes or online). <p>

59) Which of the following correctly describes the muscle, deep digital flexors?

- A. Origin - spinal column; Insertion - ilium; Innervation - ventral branch of thoracic & lumbar nerve
- B. Origin - metatarsals; Insertion - proximal sesamoid and digital extensor tendon; Innervation - tibial
- C. Origin - femur; Insertion - tibia; Innervation - femoral
- \* D. Origin - tibia, fibula; Insertion - distal phalanges; Innervation - tibial

Muscle deep digital flexors belongs to the muscle group, caudal leg. <p>It originates on the <b>tibia, fibula</b> (plantar surface of the proximal two thirds of the tibia; proximal half of the fibula & the adjacent interosseous membrane). It inserts on the <b>distal phalanges</b> (plantar surface of the base of each of the distal phalanges). <p>It flexes the digits & extends the tarsus. <p>Innervation is by the <b>tibial</b> (it also innervates the gastrocnemius, interosseous, popliteus, soleus, superficial digital flexors). <p>Blood supply is by the <b>saphenous</b> (it also supplies the superficial digital flexors). <p>Addl. Notes : blood supply assumed based on location (nothing definitive found in notes or online). <p>

60) Which of the following correctly describes the muscle, soleus?

- \* A. Origin - fibula; Insertion - calcaneous tuberosity; Innervation - tibial
- B. Origin - first rib; Insertion - thyroid cartilage; Innervation - ventral branches of cervical spinal
- C. Origin - scapula; Insertion - humerus; Innervation - subscapular
- D. Origin - humerus; Insertion - phalanges; Innervation - radial

Muscle soleus belongs to the muscle group, caudal leg. <p>It originates on the <b>fibula</b> (head of fibula). It inserts on the <b>calcaneous tuberosity</b> (tendon of lateral head of gastrocnemius, thus to calcaneous tuberosity). <p>It extends the tarsus. <p>Innervation is by the <b>tibial</b> (it also innervates the deep digital flexors, gastrocnemius, interosseous, popliteus, superficial digital flexors). <p>Blood supply is by the <b>caudal tibial or saphenous</b> (it also supplies the gastrocnemius, popliteus). <p>Addl. Notes : absent in dogs, blood supply assumed based on location (nothing definitive found in notes or online). <p>

61) Which of the following correctly describes the muscle, popliteus?

- A. Origin - ilium; Insertion - femur; Innervation - gluteal
- B. Origin - spine; Insertion - humerus; Innervation - thoracodorsal (c7,c8, t1)
- C. Origin - humerus; Insertion - olecranon; Innervation - radial
- \* D. Origin - femur; Insertion - tibia; Innervation - tibial

Muscle popliteus belongs to the muscle group, caudal leg. <p>It originates on the <b>femur</b> (distal end of femur). It inserts on the <b>tibia</b> (proximal end of tibia). <p>It flexes the stifle. <p>Innervation is by the <b>tibial</b> (it also innervates the deep digital flexors, gastrocnemius, interosseous, soleus, superficial digital flexors). <p>Blood supply is by the <b>caudal tibial or saphenous</b> (it also supplies the gastrocnemius, soleus). <p>Addl. Notes : blood supply assumed based on location (nothing definitive found in notes or online).

62) Which of the following correctly describes the muscle, interosseous?

- A. Origin - scapula; Insertion - olecranon; Innervation - radial
- B. Origin - pubis; Insertion - femur; Innervation - obturator
- \* C. Origin - metatarsals; Insertion - proximal sesamoid and digital extensor tendon; Innervation - tibial
- D. Origin - tibia, fibula; Insertion - distal phalanges; Innervation - tibial

Muscle interosseous belongs to the muscle group, caudal leg. <p>It originates on the <b>metatarsals</b> (proximal and medial metatarsals). It inserts on the <b>proximal sesamoid and digital extensor tendon</b> (extends digits). <p>Innervation is by the <b>tibial</b> (it also innervates the deep digital flexors, gastrocnemius, popliteus, soleus, superficial digital flexors). <p>Addl. Notes : an entirely tendinous muscle that is part of the suspensory ligament in the horse (only in the horse ?).

63) Which of the following correctly describes the muscle, superficial pectoral muscles (descending and transverse)?

- A. Origin - tibia; Insertion - metatarsals i & ii; Innervation - peroneal
- B. Origin - pubis; Insertion - medial stifle; Innervation - obturator
- \* C. Origin - sternum; Insertion - humerus; Innervation - cranial pectoral (c7,c8)
- D. Origin - scapula; Insertion - humerus; Innervation - axillary

Muscle superficial pectoral muscles (descending and transverse) belongs to the muscle group, synsarcosis - superficial. <p>It originates on the <b>sternum</b> (first 2 sternebrae & part of the 3rd; fibrous raphe between adjacent muscles). It inserts on the <b>humerus</b> (entire crest of the greater tubercle). <p>It adducts (toward) the limb when it is not bearing weight, to prevent the limb from being abducted when bearing weight. <p>Innervation is by the <b>cranial pectoral (c7,c8)</b> (it also innervates the \*\*\* None Found \*\*\*). <p>

64) Which of the following correctly describes the muscle, deep pectoral muscle?

- A. Origin - pubis; Insertion - femur; Innervation - obturator
- \* B. Origin - sternum; Insertion - humerus; Innervation - caudal pectoral (c8,t1)
- C. Origin - humerus; Insertion - metacarpals; Innervation - radial
- D. Origin - femur; Insertion - metatarsals; Innervation - peroneal

Muscle deep pectoral muscle belongs to the muscle group, synsarcosis - deep. <p>It originates on the <b>sternum</b> (ventral part of the sternum & fibrous raphe between fellow muscles; deep abdominal fascia in the region of the xiphoid cartilage). It inserts on the <b>humerus</b> (major portion, partly muscular, partly tendinous on lesser tubercle of humerus; an aponeurosis to the greater tubercle & crest; caudal part to the medial brachial fascia). <p>It when limb is fixed, pulls trunk cranially and extends shoulder joint; when limb is not supporting weight, draws the limb caudally and flex the shoulder joint. <p>Innervation is by the <b>caudal pectoral (c8,t1)</b> (it also innervates the \*\*\* None Found \*\*\*). <p>

65) Which of the following correctly describes the muscle, brachiocephalicus?

- \* A. Origin - humerus; Insertion - skull & neck; Innervation - accessory and ventral branches of cervical spinal
- B. Origin - sternum; Insertion - basihyoid bone; Innervation - ventral branches of cervical spinal
- C. Origin - skull; Insertion - scapula; Innervation - ventral branches of cervical and thoracic spinal
- D. Origin - humerus; Insertion - metacarpals; Innervation - radial

Muscle brachiocephalicus belongs to the muscle group, synsarcosis - superficial. <p>It originates on the <b>humerus</b> (\|). It inserts on the <b>skull & neck</b> (mastoid process in carnivores). <p>It advances the limb; extends the shoulder and draws the neck and head laterally. <p>Innervation is by the <b>accessory and ventral branches of cervical spinal</b> (it also innervates the \*\*\* None Found \*\*\*). <p>Blood supply (not sure about thoracic limb) is by the <b>in part, axillary or subclavian</b> (it also supplies the omotransversarius). <p>

66) Which of the following correctly describes the muscle, sternocephalicus: ventral or mastoid part (sternomastoideus) and dorsal or occipital part (sterno-occipitals)?

- A. Origin - scapula; Insertion - humerus; Innervation - subscapular
- B. Origin - ilium; Insertion - patella; Innervation - saphaneous
- C. Origin - humerus; Insertion - ulna, radius; Innervation - musculocutaneous
- \* D. Origin - sternum; Insertion - skull; Innervation - accessory and ventral branches pf cervical spinal

Muscle sternocephalicus: ventral or mastoid part (sternomastoideus) and dorsal or occipital part (sterno-occipitals) belongs to the muscle group, head & neck. <p>It originates on the <b>sternum</b> (manubrium). It inserts on the <b>skull</b> (mastoid part of the temporal bone and the nuchal crest of the occipital bone). <p>It draws the neck and head to the side. <p>Innervation is by the <b>accessory and ventral branches pf cervical spinal</b> (it also innervates the \*\*\* None Found \*\*\*). <p>Blood supply (not sure about thoracic limb) is by the <b>unknown</b> (it also supplies the anconeus, deep pectoral muscle, interosseous, rhomboideus, sternohyoideus, sternothyroideus, superficial pectoral muscles (descending and transverse)). <p>

67) Which of the following correctly describes the muscle, sternohyoideus?

- A. Origin - ilium; Insertion - tibia; Innervation - saphaneous
- \* B. Origin - sternum; Insertion - basihyoid bone; Innervation - ventral branches of cervical spinal
- C. Origin - ischium; Insertion - femur; Innervation - ischiatic
- D. Origin - femur; Insertion - distal phalanges ii, iii, iv, & v; Innervation - peroneal

Muscle sternohyoideus belongs to the muscle group, head & neck. <p>It originates on the <b>sternum</b> (first sternebra and 1st costal cartilage). It inserts on the <b>basihyoid bone</b> . <p>It pulls the tongue and larynx caudally. <p>Innervation is by the <b>ventral branches of cervical spinal</b> (it also innervates the sternothyroideus). < <p>

68) Which of the following correctly describes the muscle, sternothyroideus?

- A. Origin - humerus; Insertion - carpal, metacarpal; Innervation - radial
- B. Origin - humerus; Insertion - skull & neck; Innervation - accessory and ventral branches of cervical spinal
- \* C. Origin - first rib; Insertion - thyroid cartilage; Innervation - ventral branches of cervical spinal
- D. Origin - humerus; Insertion - olecranon; Innervation - radial

Muscle sternothyroideus belongs to the muscle group, head & neck. <p>It originates on the <b>first rib</b> (1st costal cartilage). It inserts on the <b>thyroid cartilage</b> (caudolateral surface of thyroid cartilage). <p>It pulls the tongue and larynx caudally. <p>Innervation is by the <b>ventral branches of cervical spinal</b> (it also innervates the sternohyoideus). < <p>

69) Which of the following correctly describes the muscle, omotransversarius?

- A. Origin - humerus; Insertion - phalanges; Innervation - radial
- B. Origin - femur; Insertion - tibia; Innervation - femoral
- \* C. Origin - atlas; Insertion - scapula; Innervation - accessory
- D. Origin - spinal column; Insertion - ilium; Innervation - ventral branch of thoracic & lumbar nerve

Muscle omotransversarius belongs to the muscle group, *synsarcosis - superficial*. <p>It originates on the <b>atlas</b> (wing of the atlas). It inserts on the <b>scapula</b> (distal end of the spine of the scapula; cranially the transverse process of the atlas). <p>It advances the limb or flexes the neck laterally. <p>Innervation is by the <b>accessory</b> (it also innervates the trapezius (cervical and thoracic parts separated by aponeurosis)). <p>Blood supply (not sure about thoracic limb) is by the <b>in part, axillary or subclavian</b> (it also supplies the brachiocephalicus). <p>

70) Which of the following correctly describes the muscle, trapezius (cervical and thoracic parts separated by aponeurosis)?

- A. Origin - scapula; Insertion - humerus; Innervation - subscapular
- \* B. Origin - spine; Insertion - scapula; Innervation - accessory
- C. Origin - humerus; Insertion - phalanges; Innervation - radial
- D. Origin - first rib; Insertion - thyroid cartilage; Innervation - ventral branches of cervical spinal

Muscle trapezius (cervical and thoracic parts separated by aponeurosis) belongs to the muscle group, *synsarcosis - superficial*. <p>It originates on the <b>spine</b> (median raphe of the neck and supraspinous ligament from the level of the 3rd cervical vertebra and to the level of the 9th thoracic vertebra.). It inserts on the <b>scapula</b> (spine of the scapula). <p>It elevates and abducts the forelimb. <p>Innervation is by the <b>accessory</b> (it also innervates the omotransversarius). <p>Blood supply (not sure about thoracic limb) is by the <b>axillary or subclavian</b> (it also supplies the \*\*\* None Found \*\*\*). <p>

71) Which of the following correctly describes the muscle, rhomboideus?

- \* A. Origin - skull; Insertion - scapula; Innervation - ventral branches of cervical and thoracic spinal
- B. Origin - humerus; Insertion - phalanges; Innervation - radial
- C. Origin - ilium; Insertion - femur; Innervation - gluteal
- D. Origin - femur; Insertion - calcaneous tuberosity; Innervation - tibial

Muscle rhomboideus belongs to the muscle group, *synsarcosis - deep*. <p>It originates on the <b>skull</b> (nuchal crest of the occipital bone; median fibrous raphe of the neck; spinous process of the first 7 thoracic vertebrae). It inserts on the <b>scapula</b> (dorsal border and adjacent surface of the scapula). <p>It elevates forelimb and draws scapula against trunk. <p>Innervation is by the <b>ventral branches of cervical and thoracic spinal</b> (it also innervates the \*\*\* None Found \*\*\*). <

72) Which of the following correctly describes the muscle, latissimus dorsi?

- A. Origin - tibia, fibula; Insertion - distal phalanges; Innervation - tibial
- B. Origin - femur; Insertion - calcaneous tuberosity; Innervation - tibial
- C. Origin - pubis; Insertion - femur; Innervation - obturator
- \* D. Origin - spine; Insertion - humerus; Innervation - thoracodorsal (c7,c8, t1)

Muscle latissimus dorsi belongs to the muscle group, synsarcosis - superficial. <p>It originates on the <b>spine</b> (thoracolumbar fascia from the spinous processes of the lumbar and the last 7 or 8 thoracic vertebrae; muscular attachment to last 2 or 3 ribs). It inserts on the <b>humerus</b> (teres major tuberosity of the humerus and teres major tendon). <p>It draws the free limb caudally as in digging; flexes the shoulder joint. <p>Innervation is by the <b>thoracodorsal (c7,c8, t1)</b> (it also innervates the \*\*\* None Found \*\*\*). <p>Blood supply (not sure about thoracic limb) is by the <b>lateral thoracic</b> (it also supplies the serratus ventralis). <p>It originates on the <b>scapula</b> (spine and acromial process of the scapula). It inserts on the <b>humerus</b> (deltoid tuberosity). <p>It flexes the shoulder. <p>Innervation is by the <b>axillary</b> (it also innervates the teres major, teres minor). <p>Blood supply (not sure about thoracic limb) is by the <b>axillary</b> (it also supplies the \*\*\* None Found \*\*\*). <p>

76) Which of the following correctly describes the muscle, teres minor?

- A. Origin - ilium; Insertion - tibia; Innervation - femoral
- B. Origin - femur; Insertion - tibia; Innervation - tibial
- \* C. Origin - scapula; Insertion - humerus; Innervation - axillary
- D. Origin - pubis; Insertion - femur; Innervation - obturator

Muscle teres minor belongs to the muscle group, caudal shoulder. <p>It originates on the <b>scapula</b> (infraglenoid tubercle & distal third of the caudal border of the scapula). It inserts on the <b>humerus</b> (teres minor tuberosity of the humerus). <p>It flexes the shoulder and rotates the arm laterally. <p>Innervation is by the <b>axillary</b> (it also innervates the deltoideus, teres major). <p>Blood supply (not sure about thoracic limb) is by the <b>brachial</b> (it also supplies the coracobrachialis). <p>

77) Which of the following correctly describes the muscle, supraspinatus?

- A. Origin - latissimus fascia; Insertion - olecranon; Innervation - radial
- B. Origin - humerus; Insertion - ulna, radius; Innervation - musculocutaneous
- C. Origin - ilium; Insertion - patella; Innervation - saphaneous
- \* D. Origin - scapula; Insertion - humerus; Innervation - subscapular

Muscle supraspinatus belongs to the muscle group, lateral shoulder. <p>It originates on the <b>scapula</b> (supraspinous fossa). It inserts on the <b>humerus</b> (greater tubercle of the humerus by a thick tendon). <p>It extends and stabilizes the shoulder joint. <p>Innervation is by the <b>subscapular</b> (it also innervates the infraspinatus, subscapularis). <p>Blood supply (not sure about thoracic limb) is by the <b>suprascapular</b> (it also supplies the \*\*\* None Found \*\*\*). <p>

78) Which of the following correctly describes the muscle, subscapularis?

- \* A. Origin - scapula; Insertion - humerus; Innervation - subscapular
- B. Origin - humerus; Insertion - carpal, metacarpal; Innervation - radial
- C. Origin - humerus; Insertion - skull & neck; Innervation - accessory and ventral branches of cervical spinal
- D. Origin - humerus; Insertion - olecranon; Innervation - radial

Muscle subscapularis belongs to the muscle group, medial shoulder. <p>It originates on the <b>scapula</b> (subscapular fossa). It inserts on the <b>humerus</b> (lesser tubercle of the humerus). <p>It adducts, extends and stabilizes the shoulder joint. rotates the arm medially. <p>Innervation is by the <b>subscapular</b> (it also innervates the infraspinatus, supraspinatus). <p>Blood supply (not sure about thoracic limb) is by the <b>subscapular</b> (it also supplies the infraspinatus, teres major). <p>

79) Which of the following correctly describes the muscle, teres major?

- \* A. Origin - scapula; Insertion - humerus; Innervation - axillary
- B. Origin - spinal column; Insertion - ilium; Innervation - ventral branch of thoracic & lumbar nerve
- C. Origin - metatarsals; Insertion - proximal sesamoid and digital extensor tendon; Innervation - tibial
- D. Origin - femur; Insertion - tibia; Innervation - femoral

Muscle teres major belongs to the muscle group, caudal shoulder. <p>It originates on the <b>scapula</b> (caudal angle and adjacent caudal border of the scapula; cranial surface of the subscapularis). It inserts on the <b>humerus</b> (teres major tuberosity of the humerus). <p>It flexes the shoulder and rotates the arm medially. <p>Innervation is by the <b>axillary</b> (it also innervates the deltoideus, teres minor). <p>Blood supply (not sure about thoracic limb) is by the <b>subscapular</b> (it also supplies the infraspinatus, subscapularis). <p>

80) Which of the following correctly describes the muscle, coracobrachialis?

- A. Origin - first rib; Insertion - thyroid cartilage; Innervation - ventral branches of cervical spinal
- \* B. Origin - scapula; Insertion - humerus; Innervation - musculocutaneous
- C. Origin - humerus; Insertion - phalanges; Innervation - radial
- D. Origin - scapula; Insertion - humerus; Innervation - subscapular

Muscle coracobrachialis belongs to the muscle group, medial shoulder. <p>It originates on the <b>scapula</b> (corocoid process of the scapula). It inserts on the <b>humerus</b> (crest of the lesser tubercle of the humerus proximal to the teres major tuberosity). <p>It adducts and extends the shoulder. <p>Innervation is by the <b>musculocutaneous</b> (it also innervates the biceps brachii, brachialis). <p>Blood supply (not sure about thoracic limb) is by the <b>brachial</b> (it also supplies the teres minor). <p>

81) Which of the following correctly describes the muscle, tensor fasciae antebrachii?

- \* A. Origin - latissimus fascia; Insertion - olecranon; Innervation - radial
- B. Origin - spine; Insertion - humerus; Innervation - thoracodorsal (c7,c8, t1)
- C. Origin - ilium; Insertion - femur; Innervation - gluteal
- D. Origin - humerus; Insertion - olecranon; Innervation - radial

Muscle tensor fasciae antebrachii belongs to the muscle group, arm extensor. <p>It originates on the <b>latissimus fascia</b> (fascia covering the lateral side of the latissimus dorsi). It inserts on the <b>olecranon</b> (olecranon tuber). <p>It extends the elbow. <p>Innervation is by the <b>radial</b> (it also innervates the anconeus, common digital extensor, extensor carpi radialis, lateral digital extensor, triceps brachii (accessory), triceps brachii (lateral), triceps brachii (long), triceps brachii (medial), ulnaris lateralis). <p>Blood supply (not sure about thoracic limb) is by the <b>axillary - deltoid branch</b> (it also supplies the \*\*\* None Found \*\*\*). <p>

82) Which of the following correctly describes the muscle, triceps brachii (long)?

- A. Origin - tibia, fibula; Insertion - distal phalanges; Innervation - tibial
- B. Origin - tibia; Insertion - metatarsals i & ii; Innervation - peroneal
- C. Origin - pubis; Insertion - femur; Innervation - obturator
- \* D. Origin - scapula; Insertion - olecranon; Innervation - radial

Muscle triceps brachii (long) belongs to the muscle group, arm extensor. <p>It originates on the <b>scapula</b> (caudal border of the scapula). It inserts on the <b>olecranon</b> (olecranon tuber). <p>It extends elbow and flexes shoulder. <p>Innervation is by the <b>radial</b> (it also innervates the anconeus, common digital extensor, extensor carpi radialis, lateral digital extensor, tensor fasciae antebrachii, triceps brachii (accessory), triceps brachii (lateral), triceps brachii (medial), ulnaris lateralis). <p>Blood supply (not sure about thoracic limb) is by the <b>deep brachial</b> (it also supplies the triceps brachii (accessory), triceps brachii (lateral), triceps brachii (medial)). <p>

84) Which of the following correctly describes the muscle, triceps brachii (accessory)?

- A. Origin - humerus; Insertion - metacarpals; Innervation - radial
- B. Origin - skull; Insertion - scapula; Innervation - ventral branches of cervical and thoracic spinal
- C. Origin - sternum; Insertion - humerus; Innervation - caudal pectoral (c8,t1)
- \* D. Origin - humerus; Insertion - olecranon; Innervation - radial

Muscle triceps brachii (accessory) belongs to the muscle group, arm extensor. <p>It originates on the <b>humerus</b> (neck of the humerus). It inserts on the <b>olecranon</b> (olecranon tuber). <p>It extends the elbow. <p>Innervation is by the <b>radial</b> (it also innervates the anconeus, common digital extensor, extensor carpi radialis, lateral digital extensor, tensor fasciae antebrachii, triceps brachii (lateral), triceps brachii (long), triceps brachii (medial), ulnaris lateralis). <p>Blood supply (not sure about thoracic limb) is by the <b>deep brachial</b> (it also supplies the triceps brachii (lateral), triceps brachii (long), triceps brachii (medial)). <p>

85) Which of the following correctly describes the muscle, triceps brachii (medial)?

- A. Origin - ilium; Insertion - tibia; Innervation - femoral
- \* B. Origin - humerus; Insertion - olecranon; Innervation - radial
- C. Origin - pubis; Insertion - femur; Innervation - obturator
- D. Origin - sternum; Insertion - basihyoid bone; Innervation - ventral branches of cervical spinal

Muscle triceps brachii (medial) belongs to the muscle group, arm extensor. <p>It originates on the <b>humerus</b> (crest of the lesser tubercle). It inserts on the <b>olecranon</b> (olecranon tuber). <p>It extends elbow. <p>Innervation is by the <b>radial</b> (it also innervates the anconeus, common digital extensor, extensor carpi radialis, lateral digital extensor, tensor fasciae antebrachii, triceps brachii (accessory), triceps brachii (lateral), triceps brachii (long), ulnaris lateralis). <p>Blood supply (not sure about thoracic limb) is by the <b>deep brachial</b> (it also supplies the triceps brachii (accessory), triceps brachii (lateral), triceps brachii (long)). <p>

86) Which of the following correctly describes the muscle, anconeus?

- A. Origin - scapula; Insertion - humerus; Innervation - subscapular
- B. Origin - humerus; Insertion - ulna, radius; Innervation - musculocutaneous
- C. Origin - ilium; Insertion - patella; Innervation - saphaneous
- \* D. Origin - humerus; Insertion - ulna; Innervation - radial

Muscle anconeus belongs to the muscle group, arm extensor. <p>It originates on the <b>humerus</b> (lateral supracondylar crest and lateral and medial epicondyle). It inserts on the <b>ulna</b> (lateral surface of the proximal end of the ulna). <p>It extends the elbow. <p>Innervation is by the <b>radial</b> (it also innervates the common digital extensor, extensor carpi radialis, lateral digital extensor, tensor fasciae antebrachii, triceps brachii (accessory), triceps brachii (lateral), triceps brachii (long), triceps brachii (medial), ulnaris lateralis). <p>

87) Which of the following correctly describes the muscle, biceps brachii?

- A. Origin - ilium; Insertion - patella; Innervation - saphaneous
- \* B. Origin - scapula; Insertion - ulna, radius; Innervation - musculocutaneous
- C. Origin - latissimus fascia; Insertion - olecranon; Innervation - radial
- D. Origin - femur; Insertion - tibia; Innervation - tibial

Muscle biceps brachii belongs to the muscle group, arm flexor. <p>It originates on the <b>scapula</b> (supraglenoid tubercle). It inserts on the <b>ulna, radius</b> (ulnar and radial tuberosities). <p>It flexes elbow and extends shoulder. <p>Innervation is by the <b>musculocutaneous</b> (it also innervates the brachialis, coracobrachialis). <p>Blood supply (not sure about thoracic limb) is by the <b>bicipetal (off brachial)</b> (it also supplies the brachialis). <p>

88) Which of the following correctly describes the muscle, brachialis?

- A. Origin - humerus; Insertion - skull & neck; Innervation - accessory and ventral branches of cervical spinal
- \* B. Origin - humerus; Insertion - ulna, radius; Innervation - musculocutaneous
- C. Origin - humerus; Insertion - olecranon; Innervation - radial
- D. Origin - humerus; Insertion - carpal, metacarpal; Innervation - radial

Muscle brachialis belongs to the muscle group, arm flexor. <p>It originates on the <b>humerus</b> (proximal third of the lateral side of the humerus). It inserts on the <b>ulna, radius</b> (ulnar and radial tuberosities). <p>It flexes elbow. <p>Innervation is by the <b>musculocutaneous</b> (it also innervates the biceps brachii, coracobrachialis). <p>Blood supply (not sure about thoracic limb) is by the <b>bicipetal (off brachial)</b> (it also supplies the biceps brachii). <p>

89) Which of the following correctly describes the muscle, extensor carpi radialis?

- A. Origin - metatarsals; Insertion - proximal sesamoid and digital extensor tendon; Innervation - tibial
- \* B. Origin - humerus; Insertion - metacarpals; Innervation - radial
- C. Origin - femur; Insertion - tibia; Innervation - femoral
- D. Origin - spinal column; Insertion - ilium; Innervation - ventral branch of thoracic & lumbar nerve

Muscle extensor carpi radialis belongs to the muscle group, carpus/digit extensor. <p>It originates on the <b>humerus</b> (lateral supracondylar crest). It inserts on the <b>metacarpals</b> (small tuberosities on the dorsal surface of the base of metacarpals ii and iii). <p>It extends carpus. <p>Innervation is by the <b>radial</b> (it also innervates the anconeus, common digital extensor, lateral digital extensor, tensor fasciae antebrachii, triceps brachii (accessory), triceps brachii (lateral), triceps brachii (long), triceps brachii (medial), ulnaris lateralis). <p>Blood supply (not sure about thoracic limb) is by the <b>cranial superficial antibrachial (off superficial brachial)</b> (it also supplies the common digital extensor). <p>

90) Which of the following correctly describes the muscle, common digital extensor?

A. Origin - first rib; Insertion - thyroid cartilage; Innervation - ventral branches of cervical spinal

\* B. Origin - humerus; Insertion - phalanges; Innervation - radial

C. Origin - humerus; Insertion - phalanges; Innervation - radial

D. Origin - scapula; Insertion - humerus; Innervation - subscapular

Muscle common digital extensor belongs to the muscle group, carpus/digit extensor. <p>It originates on the <b>humerus</b> (lateral epicondyle of the humerus). It inserts on the <b>phalanges</b> (extensor processes of the distal phalanges of digits ii, iii, iv, and v). <p>It extends joints of the four principal digits and the carpus. <p>Innervation is by the <b>radial</b> (it also innervates the anconeus, extensor carpi radialis, lateral digital extensor, tensor fasciae antebrachii, triceps brachii (accessory), triceps brachii (lateral), triceps brachii (long), triceps brachii (medial), ulnaris lateralis). <p>Blood supply (not sure about thoracic limb) is by the <b>cranial superficial antibrachial (off superficial brachial)</b> (it also supplies the extensor carpi radialis). <p>

91) Which of the following correctly describes the forelimb muscle, lateral digital extensor?

A. Origin - spine; Insertion - humerus; Innervation - thoracodorsal (c7,c8, t1)

\* B. Origin - humerus; Insertion - phalanges; Innervation - radial

C. Origin - ilium; Insertion - femur; Innervation - gluteal

D. Origin - humerus; Insertion - phalanges; Innervation - radial

Muscle lateral digital extensor belongs to the muscle group, carpus/digit extensor. <p>It originates on the <b>humerus</b> (lateral epicondyle of the humerus). It inserts on the <b>phalanges</b> (proximal ends of all the phalanges of digits iii, iv, and v, but mainly the extensor processes of the distal phalanges of these digits). <p>It extends the carpus and joints of digits iii, iv, and v. <p>Innervation is by the <b>radial</b> (it also innervates the anconeus, common digital extensor, extensor carpi radialis, tensor fasciae antebrachii, triceps brachii (accessory), triceps brachii (lateral), triceps brachii (long), triceps brachii (medial), ulnaris lateralis). <p>Blood supply (not sure about thoracic limb) is by the <b>any or all of interosseous, radial, median</b> (it also supplies the \*\*\* None Found \*\*\*). <p>

92) Which of the following correctly describes the muscle, ulnaris lateralis?

A. Origin - tibia, fibula; Insertion - distal phalanges; Innervation - tibial

B. Origin - femur; Insertion - calcaneous tuberosity; Innervation - tibial

C. Origin - pubis; Insertion - femur; Innervation - obturator

\* D. Origin - humerus; Insertion - carpal, metacarpal; Innervation - radial

Muscle ulnaris lateralis belongs to the muscle group, carpus/digit extensor. <p>It originates on the <b>humerus</b> (lateral epicondyle of humerus). It inserts on the <b>carpal, metacarpal</b> (lateral aspect of the proximal end of metacarpal v and the accessory carpal). <p>It abducts and flexes the carpus. <p>Innervation is by the <b>radial</b> (it also innervates the anconeus, common digital extensor, extensor carpi radialis, lateral digital extensor, tensor fasciae antebrachii, triceps brachii (accessory), triceps brachii (lateral), triceps brachii (long), triceps brachii (medial)). <p>Blood supply (not sure about thoracic limb) is by the <b>any or all of interosseous, radial, median, ulnaris</b> (it also supplies the \*\*\* None Found \*\*\*). <p>

93) Which of the following correctly describes the muscle, flexor carpi radialis?

- A. Origin - scapula; Insertion - olecranon; Innervation - radial
- B. Origin - tibia, fibula; Insertion - distal phalanges; Innervation - tibial
- C. Origin - tibia; Insertion - metatarsals i & ii; Innervation - peroneal
- \* D. Origin - humerus, radius; Insertion - metacarpal ii & iii; Innervation - median

Muscle flexor carpi radialis belongs to the muscle group, carpus/digit flexor. <p>It originates on the <b>humerus, radius</b> (medial epicondyle of humerus and medial border of the radius). It inserts on the <b>metacarpal ii & iii</b> (palmar side of the base of metacarpals ii and iii). <p>It flexes the carpus. <p>Innervation is by the <b>median</b> (it also innervates the superficial digital flexor). <p>Blood supply (not sure about thoracic limb) is by the <b>any or all of interosseous, median, ulnaris</b> (it also supplies the superficial digital flexor). <p>

94) Which of the following correctly describes the muscle, superficial digital flexor?

- A. Origin - pubis; Insertion - medial stifle; Innervation - obturator
- B. Origin - scapula; Insertion - humerus; Innervation - axillary
- C. Origin - femur; Insertion - metatarsals; Innervation - peroneal
- \* D. Origin - humerus; Insertion - metacarpals; Innervation - median

Muscle superficial digital flexor belongs to the muscle group, carpus/digit flexor. <p>It originates on the <b>humerus</b> (medial epicondyle of humerus). It inserts on the <b>metacarpals</b> (palmar surface of the base of the middle phalanges of digits ii, iii, iv, and v). <p>It flexes the carpus, metacarpophalangeal and proximal interphalangeal joints of digits ii, iii, iv, v. <p>Innervation is by the <b>median</b> (it also innervates the flexor carpi radialis). <p>Blood supply (not sure about thoracic limb) is by the <b>any or all of interosseous, median, ulnaris</b> (it also supplies the flexor carpi radialis). <p>

95) Which of the following correctly describes the muscle, flexor carpii ulnaris ( ulnar and humeral head)?

- A. Origin - sternum; Insertion - humerus; Innervation - caudal pectoral (c8,t1)
- B. Origin - humerus; Insertion - metacarpals; Innervation - radial
- C. Origin - skull; Insertion - scapula; Innervation - ventral branches of cervical and thoracic spinal
- \* D. Origin - humerus, ulna; Insertion - accessory carpal bone; Innervation - ulnar

Muscle flexor carpii ulnaris ( ulnar and humeral head belongs to the muscle group, carpus/digit flexor. <p>It originates on the <b>humerus, ulna</b> (ulnar head- caudal border and medial surface of the olecranon; humeral head- medial epicondyle of the humerus). It inserts on the <b>accessory carpal bone</b> . <p>It flexes carpus. <p>Innervation is by the <b>ulnar</b> (it also innervates the \*\*\* None Found \*\*\*). <p>Blood supply (not sure about thoracic limb) is by the <b>median</b> (it also supplies the deep digital flexor (humeral, ulnar and radial head)). <p>

96) Which of the following correctly describes the muscle, deep digital flexor (humeral, ulnar and radial head)?

- A. Origin - ilium; Insertion - tibia; Innervation - femoral
- B. Origin - sternum; Insertion - basihyoid bone; Innervation - ventral branches of cervical spinal
- C. Origin - pubis; Insertion - femur; Innervation - obturator
- \* D. Origin - humerus, radius; Insertion - phalanges; Innervation - median and ulnar

Muscle deep digital flexor (humeral, ulnar and radial head) belongs to the muscle group, carpus/digit flexor. <p>It originates on the <b>humerus, radius, ulna</b> (humeral head- medial epicondyle of the humerus; ulnar head- proximal  $\frac{3}{4}$  of the caudal border of the ulna; radial head- middle 1/3 of the medial border of the radius). It inserts on the <b>phalanges</b> (palmar surface of the base (proximal end) of the distal phalanx of each digit). <p>It flexes the carpus, metacarpophalangeal joint, and the proximal distal interphalangeal joints of the digits. <p>Innervation is by the <b>median and ulnar</b> (it also innervates the \*\*\* None Found \*\*\*). <p>Blood supply (not sure about thoracic limb) is by the <b>median</b> (it also supplies the flexor carpii ulnaris ( ul;nar and humeral head). <p>